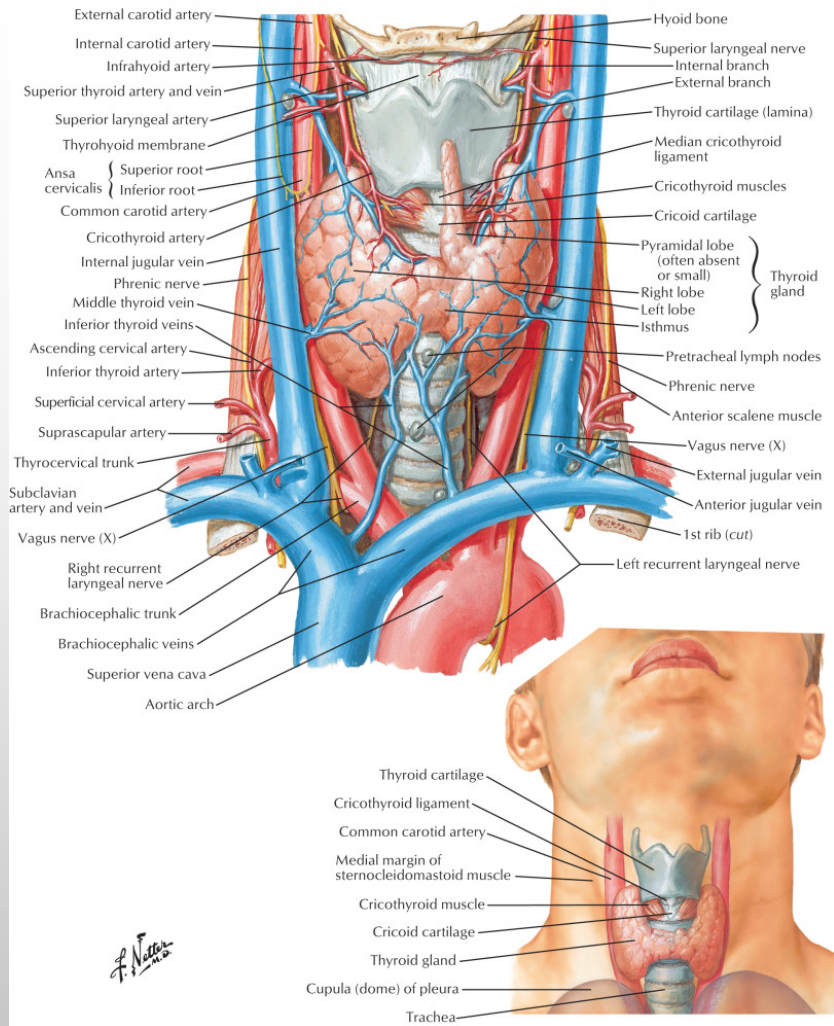


# OVERVIEW OF THYROID DISORDERS

NATASHA N. BRAY, DO, MSED, FACOI, FACP  
CLINICAL ASSOCIATE PROFESSOR OF RURAL MEDICINE – INTERNAL MEDICINE  
ASSOCIATE DEAN FOR ACADEMIC AFFAIRS AND ACCREDITATION  
OKLAHOMA STATE UNIVERSITY COLLEGE OF OSTEOPATHIC MEDICINE –  
CHEROKEE NATION



- LENGTH: 5 CM

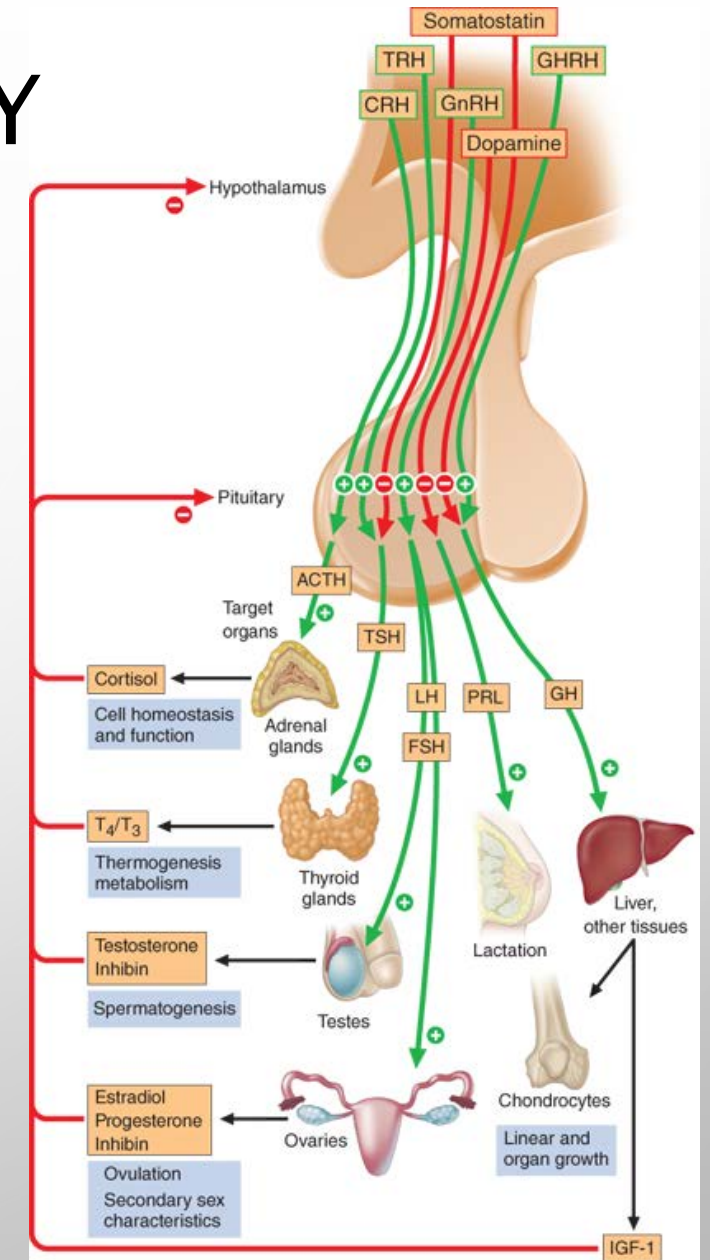
- WIDTH: 2 CM

- DEPTH: 2 CM

- WEIGHT 10-20 GRAMS

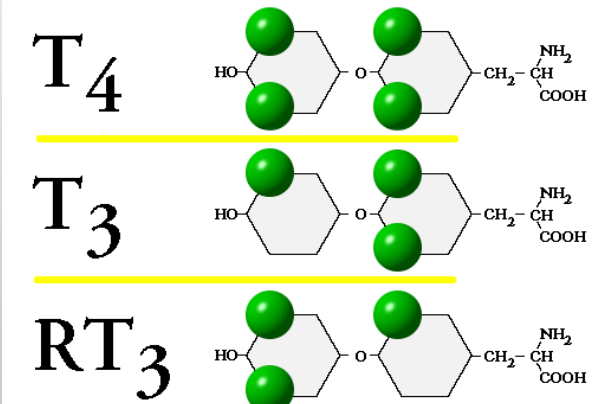
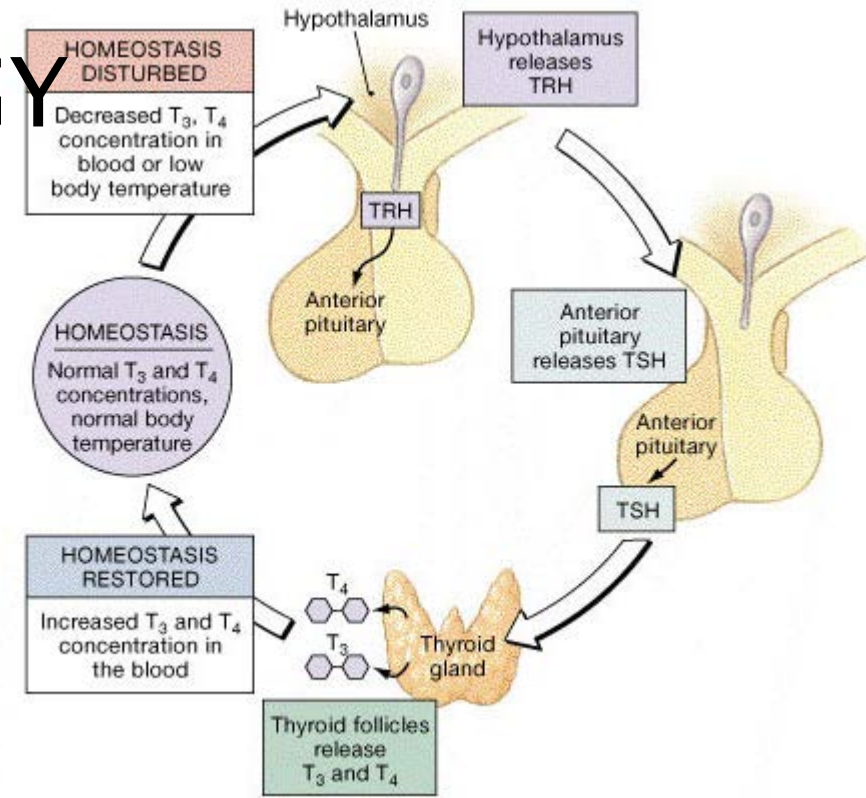
# THYROID PHYSIOLOGY

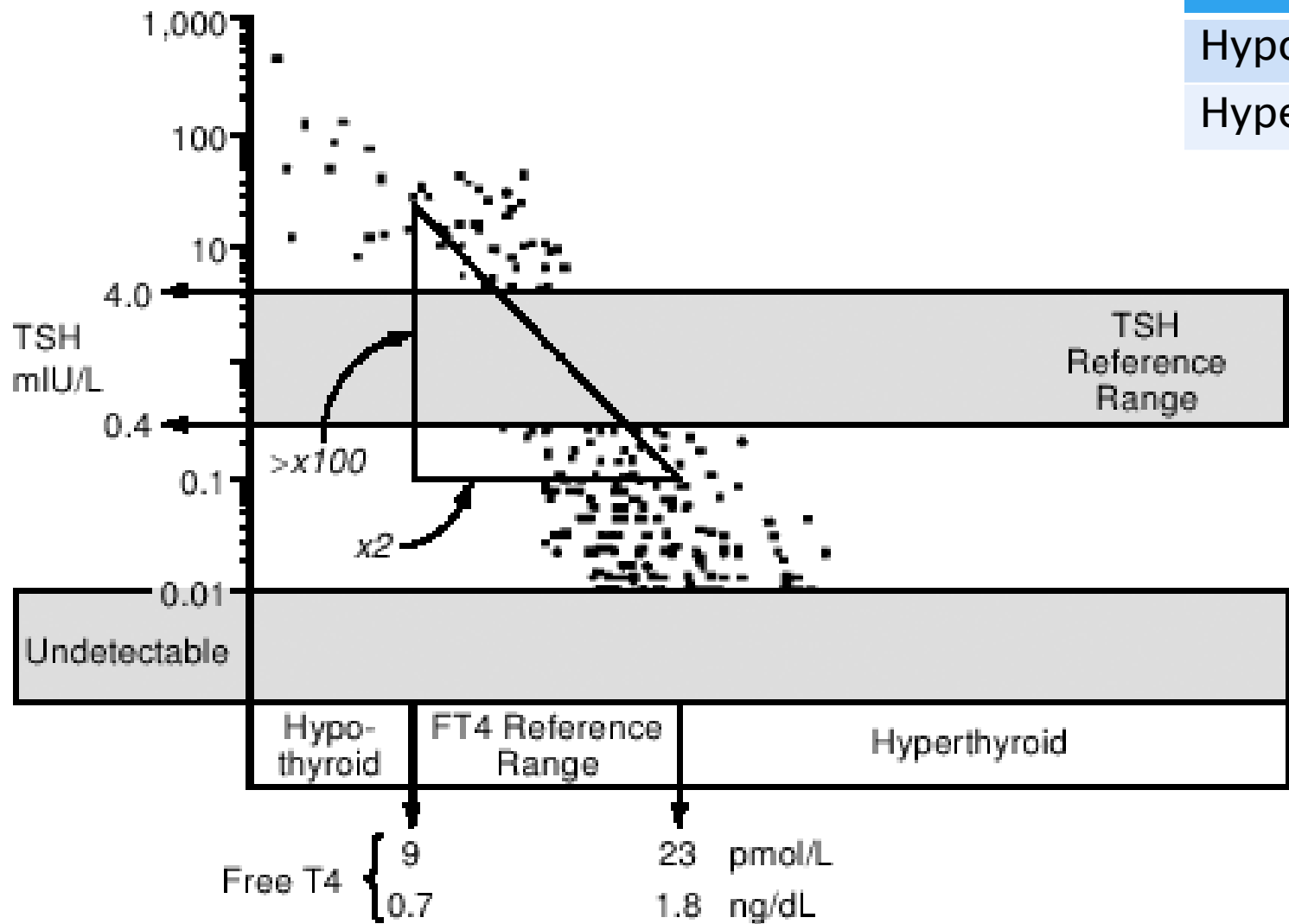
- ACTIVE THYROID HORMONE
  - THYROXINE (T4) AND TRIIODOTHYRONINE (T3)
- IODINE IS CRITICAL TO FORMATION OF THYROID HORMONE
  - DIETARY SOURCES – SEAFOOD, DAIRY PRODUCTS, IODIZED SALT
  - IODINE DEFICIENCY IN US IS RARE
- REGULATION
  - TSH SECRETION
  - PERIPHERAL CONVERSION OF T4 TO T3
- T4:T3 SECRETION BY THYROID GLAND 20:1
  - MOST T3 (80%) RESULTS FROM 5'-DEIODINATION OF T4 IN PERIPHERAL TISSUE



# THYROID PHYSIOLOGY

- THYROXINE-BINDING GLOBULIN (TBG)
  - TRANSPORT T3 & T4
- ONLY FREE T4 AND FREE T3 ARE METABOLICALLY ACTIVE
- IN THE SERUM, 0.04% OF TOTAL T4 AND T3 ARE IN FREE OR ACTIVE FORMS
- T3 HAS UP TO 10 TIMES THE POTENCY OF T4



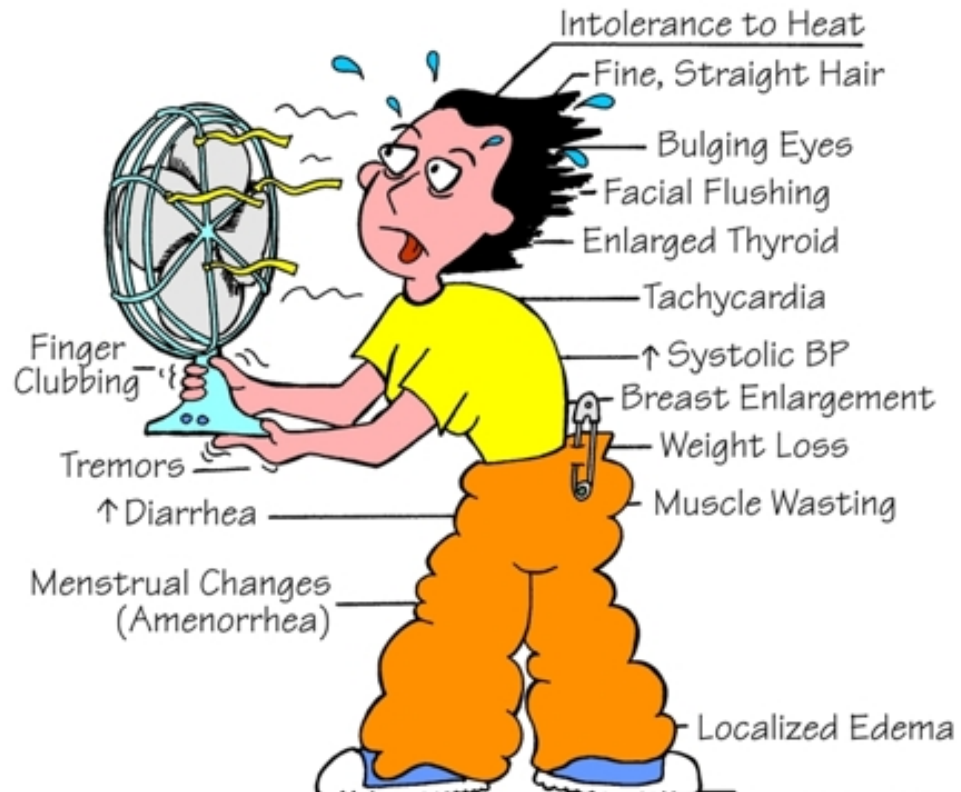


	TSH	Free T4
Hypothyroid	High	Low
Hyperthyroid	Low	High



# CLINICAL PRESENTATION

## HYPERTHYROIDISM



## HYPOTHYROIDISM



# QUESTION #1

- 36-YEAR-OLD FEMALE REPORTS INSOMNIA, WEIGHT LOSS AND ANXIETY OVER THE PAST 8-10 WEEKS. SHE DID NOT GET HER PERIOD THIS MONTH.
- PHYSICAL EXAM
  - ALERT AND ORIENTED
  - VITAL SIGNS ARE NORMAL
  - THYROID GLAND IS DIFFUSELY ENLARGED. NO DISCRETE NODULE PALPATED.
  - NO EXOPHTHALMOS
  - NO PRETIBIAL MYXEDEMA

# QUESTION #1

- 36-YEAR-OLD FEMALE REPORTS INSOMNIA, WEIGHT LOSS AND ANXIETY OVER THE PAST 8-10 WEEKS. SHE DID NOT GET HER PERIOD THIS MONTH.
- PHYSICAL EXAM
  - ALERT AND ORIENTED
  - VITAL SIGNS ARE NORMAL
  - THYROID GLAND IS DIFFUSELY ENLARGED. NO DISCRETE NODULE PALPATED.
  - NO EXOPHTHALMOS
  - NO PRETIBIAL MYXEDEMA

WHAT LAB RESULTS WOULD YOU EXPECT TO FIND?

- A. LOW TSH, LOW FREE T4, HIGH T3
- B. HIGH TSH, HIGH FREE T4, +TPO ANTIBODIES
- C. LOW TSH, HIGH FREE T4, +TPO ANTIBODIES
- D. HIGH TSH, HIGH FREE T3, -TPO ANTIBODIES
- E. LOW TSH, LOW FREE T4, +TPO ANTIBODIES



# QUESTION #1

- 36-YEAR-OLD FEMALE REPORTS INSOMNIA, WEIGHT LOSS AND ANXIETY OVER THE PAST 8-10 WEEKS. SHE DID NOT GET HER PERIOD THIS MONTH.
- PHYSICAL EXAM
  - ALERT AND ORIENTED
  - VITAL SIGNS ARE NORMAL
  - THYROID GLAND IS DIFFUSELY ENLARGED. NO DISCRETE NODULE PALPATED.
  - NO EXOPHTHALMOS
  - NO PRETIBIAL MYXEDEMA

WHAT LAB RESULTS WOULD YOU EXPECT TO FIND?

- A. LOW TSH, LOW FREE T4, HIGH T3
- B. HIGH TSH, HIGH FREE T4, +TPO ANTIBODIES
- C. LOW TSH, HIGH FREE T4,  
+TPO ANTIBODIES**
- D. HIGH TSH, HIGH FREE T3, -TPO ANTIBODIES
- E. LOW TSH, LOW FREE T4, +TPO ANTIBODIES

# QUESTION #1

- 36-YEAR-OLD FEMALE REPORTS INSOMNIA, WEIGHT LOSS AND ANXIETY OVER THE PAST 8-10 WEEKS. SHE DID NOT GET HER PERIOD THIS MONTH.
- PHYSICAL EXAM
  - ALERT AND ORIENTED
  - VITAL SIGNS ARE NORMAL
  - THYROID GLAND IS DIFFUSELY ENLARGED. NO DISCRETE NODULE PALPATED.
  - NO EXOPHTHALMOS
  - NO PRETIBIAL MYXEDEMA

WHAT IS THE MOST LIKELY CAUSE OF HER HYPERTHYROIDISM?

- A. TOXIC MULTINODULAR GOITER
- B. GRAVES' DISEASE
- C. SUBACUTE THYROIDITIS
- D. IODINE INGESTION
- E. TOXIC ADENOMA (HOT NODULE)

# QUESTION #1

- 36-YEAR-OLD FEMALE REPORTS INSOMNIA, WEIGHT LOSS AND ANXIETY OVER THE PAST 8-10 WEEKS. SHE DID NOT GET HER PERIOD THIS MONTH.
- PHYSICAL EXAM
  - ALERT AND ORIENTED
  - VITAL SIGNS ARE NORMAL
  - THYROID GLAND IS DIFFUSELY ENLARGED. NO DISCRETE NODULE PALPATED.
  - NO EXOPHTHALMOS
  - NO PRETIBIAL MYXEDEMA

WHAT IS THE MOST LIKELY CAUSE OF HER HYPERTHYROIDISM?

A. TOXIC MULTINODULAR GOITER

**B. GRAVES' DISEASE**

C. SUBACUTE THYROIDITIS

D. IODINE INGESTION

E. TOXIC ADENOMA (HOT NODULE)

# HYPERTHYROIDISM – CLINICAL PRESENTATION

- DECREASED BONE DENSITY
- ELEVATED BIOCHEMICAL MARKERS OF BONE RESORPTION:
  - INCREASED OSTEOCALCIN
  - INCREASED URINARY HYDROXYPROLINE
- INCREASED SERUM GLUCOSE
- INCREASED SERUM CA AND ALK PHOS.
- DECREASED LDL AND CHOLESTEROL
- INCREASED HEPATIC ENZYME AND CREATINE KINASE
- INCREASED SEX HORMONE BINDING
- INCREASED HEART RATE
- PRESENCE OF ATRIAL FIBRILLATION
- INCREASED CARDIAC CONTRACTILITY
- INCREASED LV MASS INDEX
- EXOPHTHALMOS OR SPECIFIC OPHTHALMOPATHY
- LARGE, TENDER THYROID
- RESTLESS AND IRRITABILITY
- WEIGHT LOSS
- FINGER TREMOR

# HYPERTHYROIDISM – ETIOLOGY

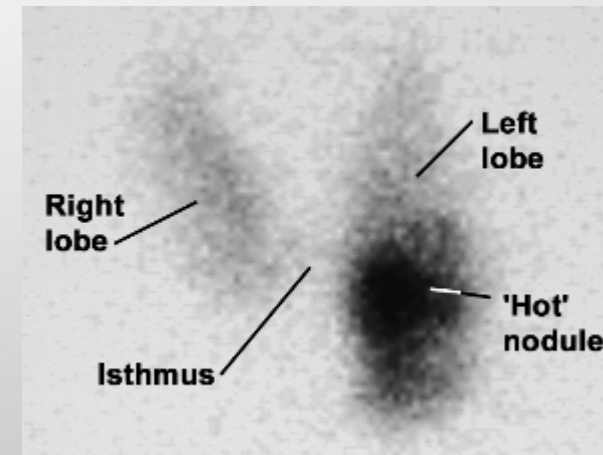
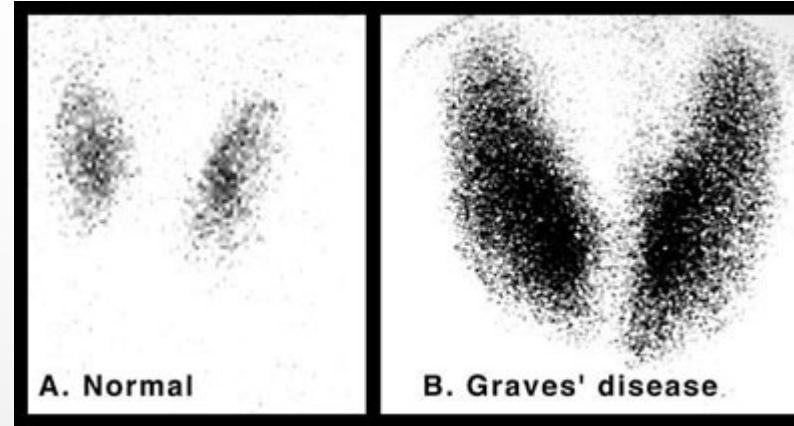
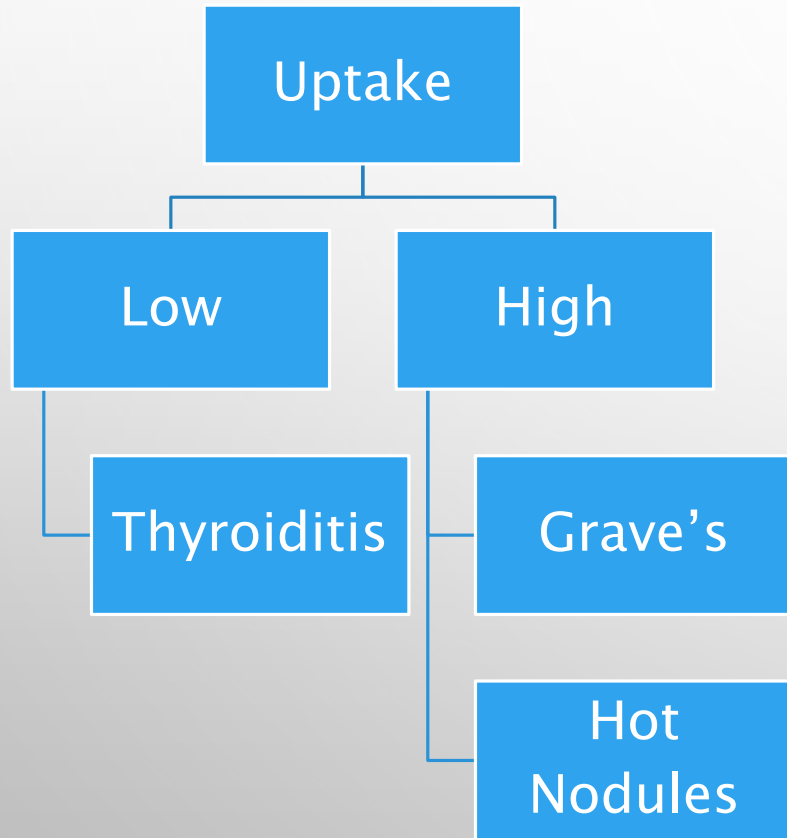
## NORMAL OR HIGH RADIOIODINE UPTAKE

- AUTOIMMUNE THYROID DISEASE
  - GRAVES' DISEASE
  - HASHITOXICOSIS
- AUTONOMOUS THYROID TISSUE
  - TOXIC ADENOMA
  - TOXIC MULTINODULAR GOITER
- TSH-MEDIATED HYPERTHYROIDISM
  - TSH-PRODUCING PITUITARY ADENOMA
  - NON-NEOPLASTIC TSH-MEDIATED HYPERTHYROIDISM
    - MUTATION IN NUCLEAR TRIIODOTHYRONINE (T3) RECEPTOR
    - MUTATION OF TSH RECEPTOR
- HUMAN CHORIONIC GONADOTROPIN-MEDIATED HYPERTHYROIDISM
  - HYPEREMESIS GRAVIDUM
  - TROPHOBLASTIC DISEASE

## ABSENT (OR NEAR) RADIOIODINE UPTAKE

- THYROIDITIS
  - SUBACUTE GRANULOMATOUS (DE QUERVAIN'S) THYROIDITIS
  - PAINLESS THYROIDITIS (SILENT THYROIDITIS, LYMPHOCYTIC THYROIDITIS)
    - POSTPARTUM THYROIDITIS
  - AMIODARONE (ALSO MAY CAUSE IODINE-INDUCED HYPERTHYROIDISM)
  - RADIATION THYROIDITIS
  - PALPATION THYROIDITIS
- EXOGENOUS THYROID HORMONE INTAKE
  - EXCESSIVE REPLACEMENT THERAPY
  - INTENTIONAL SUPPRESSIVE THERAPY
  - FACTITIOUS HYPERTHYROIDISM
- ECTOPIC HYPERTHYROIDISM
  - STRUMA OVARII
  - METASTATIC FOLLICULAR THYROID CANCER

# ROLE OF THE I-123 (I-131) UPTAKE





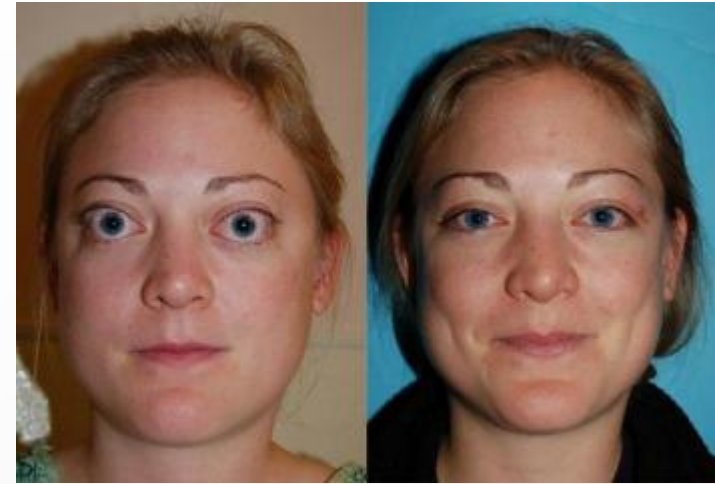# DIFFERENTIAL DIAGNOSIS

- EUTHYROID HYPERTHYROXINEMIA
  - ABNORMAL THYROID HORMONE-BINDING HORMONE
    - HIGH T4, NORMAL-HIGH T3, NORMAL TSH
- LOW SERUM TSH WITHOUT HYPERTHYROIDISM
  - CENTRAL HYPOTHYROIDISM (LOW TSH, NORMAL FT4 & T3)
  - NONTHYROIDAL ILLNESS
  - RECOVERY FROM HYPERTHYROIDISM
  - PREGNANCY – PHYSIOLOGIC LOWERING OF TSH
  - HEALTHY OLDER PATIENT – ALTERED SET POINT OF THE HYPOTHALAMIC-PITUITARY-THYROID AXIS
- BIOTIN INGESTION
  - INTERFERENCE WITH THE ASSAY → FALSELY LOW TSH AND HIGH T4 & T3

# GRAVES DISEASE

Hyperthyroidism, goiter, ophthalmopathy (orbitopathy), & pretibial/localized myxedema

- THYROTROPIN RECEPTOR SIMULATION ANTIBODIES (TSHR-AB)
  - INCREASE THYROID HORMONE SYNTHESIS, SECRETION, AND HYPERTROPHY OF THYROID GLAND
- MCC OF HYPERTHYROIDISM IN US
- LABORATORY FINDINGS
  - ELEVATED T4 & T3
  - DEPRESSED TSH
  - POSITIVE TSHR-AB
    - MAY HAVE ANTI-TG AND ANTI-TPO
  - ELEVATED RADIOIODINE UPTAKE
    - (I-123 OR TC-99)



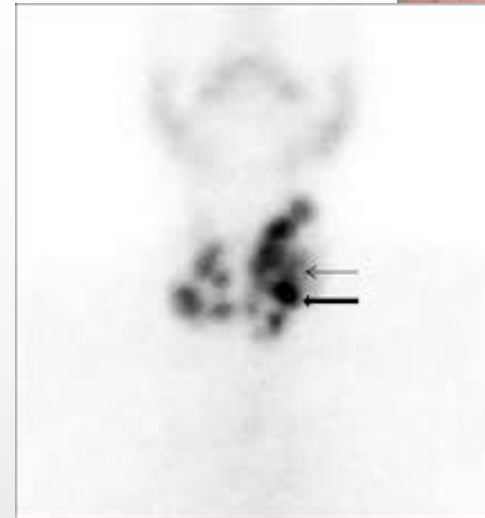
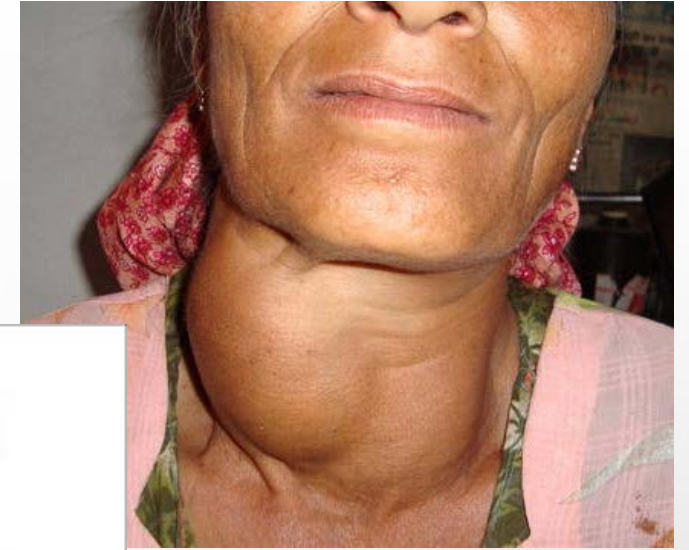- TREATMENT –
  - ANTI-THYROID MEDICATIONS (METHIMAZOLE OR PTU)
    - FIRST-LINE, MAY INDUCE LONG-TERM REMISSION.
    - NO REMISSION ACHIEVED BY 1-2 YEARS RAI ABLATION OR THYROIDECTOMY MAY BE CONSIDERED
  - BETA BLOCKERS
    - TREAT SYMPTOMS
    - PROPRANOLOL INHIBITS PERIPHERAL CONVERSION OF T4 TO T3
- EXOPHTHALMOS
  - TAPERING STEROID DOSE (6-12 WEEKS)
  - EYE SURGERY INDICATED IF DIPLOPIA OR LOSS OF VISION

# HASHITOXICOSIS

- AUTOIMMUNE THYROID DISEASE
  - HYPERTHYROID BEFORE DETERIORATION INTO HYPOTHYROID STATE
  - TSH RECEPTOR BLOCKER & TSH RECEPTOR STIMULATION GENES/AB PRESENT

# TOXIC MULTINODULAR GOITER

- ELDERLY WOMEN
- FOCAL OR DIFFUSE HYPERPLASIA OF THYROID FOLLICULAR CELLS
  - INDEPENDENT OF TSH REGULATION
- MORE COMMON IN AREAS WITH LOW IODINE INTAKE
- CLINICAL FINDINGS:
  - MASS EFFECT ON NEIGHBORING STRUCTURES – AIRWAY OBSTRUCTION AND DYSPHAGIA
  - NO EXOPHTHALMOS OR PRETIBIAL MYXEDEMA
- LAB FINDINGS
  - LOW TSH, HIGH T4
  - INCREASED RADIOIODINE UPTAKE



- TREATMENT
  - ANTI-THYROID MEDICATION (THIONAMIDE)
  - SUBTOTAL THYROIDECTOMY
  - RADIOIODINE ABLATION

# THIONAMIDES (METHIMAZOLE, PROPYLTHIOURACIL)

- INHIBIT PRODUCTION OF THYROID HORMONES (ORGANIFICATION OF IODINE TO TYROSINE AND COUPLING OF IODOTYROSINES TO FORM T3 AND T4)
  - *MAY ALSO INHIBIT THYROID HORMONE SECRETION*
  - *MAY HAVE IMMUNOMODULATORY ACTIVITY ON AUTOIMMUNE DISEASE*

- Methimazole
- Preferred due to less side effects and toxicity, longer duration of action, more rapid efficacy
- Starting dose 10-15 mg daily (larger goiter/sever symptoms 20-30 mg/day)
- Maintenance dose is 5 – 15 mg daily
- Duration of therapy generally 12 to 18 months, but has been used for up to 10 years safely
- Permanent remission after cessation of therapy in only 20-30% of patients

- Propylthiouracil (PTU)
- Drug of choice in pregnancy patients due to teratogenic effects of methimazole
- Dosage 300 – 450 mg daily initially in 2 to 3 doses
- Maintenance dose is 50 – 300 mg in 2 to 3 doses

## PRINCIPLE SIDE EFFECTS

RASH

NAUSEA

HEPATITIS

VASCULITIS

AGRANULOCYTOSIS

MORE COMMON

WITH PTU

## RADIOIODINE ABLATION

- THERAPY OF CHOICE IN US (69%)
  - USED LESS IN EUROPE (22%) & JAPAN (11%)
- I-131 CAPSULE (OR ORAL SOLUTION)
- ABLATION REQUIRES 6-18 WEEKS FOR EUTHYROID STATE
  - 20% WILL NEED SECOND ROUND OF TREATMENT

## SURGERY

- INDICATED FOR:
  - OBSTRUCTIVE GOITER
  - PREGNANT WOMEN
  - IODINE ALLERGY
  - REFUSAL OF RADIATION THERAPY



# QUESTION #2

- A 32-YEAR-OLD MAN IS EVALUATED FOR A 1-WEEK HISTORY OF SEVERE NECK PAIN. HE ALSO HAS HEAT INTOLERANCE, PALPITATIONS, AND INSOMNIA. MEDICAL HISTORY IS SIGNIFICANT ONLY FOR A VIRAL UPPER RESPIRATORY TRACT INFECTION 3 WEEKS AGO. HE TAKES NO MEDICATIONS.
- PHYSICAL EXAMINATION
  - ANXIOUS, SWEATING
  - T - 36.9 °C (98.6 °F), BP - 124/64 MM HG, P - 118/MIN, RR - 12/MIN
  - NO PROPTOSIS OR LID LAG
  - HEART: REGULAR, TACHYCARDIC, NO MURMUR
  - LUNGS: CLEAR TO AUSCULTATION BILATERALLY
  - THYROID GLAND: NORMAL-SIZED, VERY TENDER TO PALPATION. NO THYROID NODULES PALPATED.
- LABORATORY EVALUATION
  - TSH: <0.008 MU/ML (0.008 MU/L)
  - FREE-T<sub>4</sub>: 3.2 NG/DL (41.3 PMOL/L)
  - TOTAL T3: 310 NG/DL (4.8 NMOL/L)
  - THYROID-STIMULATING IMMUNOGLOBIN INDEX: <1.3 (NORMAL, <1.3)
  - 24-HOUR RADIOACTIVE IODINE UPTAKE: 5% (LOW)

# QUESTION #2

- A 32-YEAR-OLD MAN IS EVALUATED FOR A 1-WEEK HISTORY OF SEVERE NECK PAIN. HE ALSO HAS HEAT INTOLERANCE, PALPITATIONS, AND INSOMNIA. MEDICAL HISTORY IS SIGNIFICANT ONLY FOR A VIRAL UPPER RESPIRATORY TRACT INFECTION 3 WEEKS AGO. HE TAKES NO MEDICATIONS.
- PHYSICAL EXAMINATION
  - ANXIOUS, SWEATING
  - T - 36.9 °C (98.6 °F), BP - 124/64 MM HG, P - 118/MIN, RR - 12/MIN
  - NO PROPTOSIS OR LID LAG
  - HEART: REGULAR, TACHYCARDIC, NO MURMUR
  - LUNGS: CLEAR TO AUSCULTATION BILATERALLY
  - THYROID GLAND: NORMAL-SIZED, VERY TENDER TO PALPATION. NO THYROID NODULES PALPATED.
- LABORATORY EVALUATION
  - TSH: <0.008 MU/ML (0.008 MU/L)
  - FREE-T<sub>4</sub>: 3.2 NG/DL (41.3 PMOL/L)
  - TOTAL T3: 310 NG/DL (4.8 NMOL/L)
  - THYROID-STIMULATING IMMUNOGLOBIN INDEX: <1.3 (NORMAL, <1.3)
  - 24-HOUR RADIOACTIVE IODINE UPTAKE: 5% (LOW)

WHICH OF THE FOLLOWING IS THE MOST APPROPRIATE TREATMENT

A. METHIMAZOLE

B. METOPROLOL

C. PROPYLTHIOURACIL

D. RADIOACTIVE IODINE

# QUESTION #2

- A 32-YEAR-OLD MAN IS EVALUATED FOR A 1-WEEK HISTORY OF SEVERE NECK PAIN. HE ALSO HAS HEAT INTOLERANCE, PALPITATIONS, AND INSOMNIA. MEDICAL HISTORY IS SIGNIFICANT ONLY FOR A VIRAL UPPER RESPIRATORY TRACT INFECTION 3 WEEKS AGO. HE TAKES NO MEDICATIONS.
- PHYSICAL EXAMINATION
  - ANXIOUS, SWEATING
  - T - 36.9 °C (98.6 °F), BP - 124/64 MM HG, P - 118/MIN, RR - 12/MIN
  - NO PROPTOSIS OR LID LAG
  - HEART: REGULAR, TACHYCARDIC, NO MURMUR
  - LUNGS: CLEAR TO AUSCULTATION BILATERALLY
  - THYROID GLAND: NORMAL-SIZED, VERY TENDER TO PALPATION. NO THYROID NODULES PALPATED.
- LABORATORY EVALUATION
  - TSH: <0.008 MU/ML (0.008 MU/L)
  - FREE-T<sub>4</sub>: 3.2 NG/DL (41.3 PMOL/L)
  - TOTAL T3: 310 NG/DL (4.8 NMOL/L)
  - THYROID-STIMULATING IMMUNOGLOBIN INDEX: <1.3 (NORMAL, <1.3)
  - 24-HOUR RADIOACTIVE IODINE UPTAKE: 5% (LOW)

WHICH OF THE FOLLOWING IS THE MOST APPROPRIATE TREATMENT

A. METHIMAZOLE

**B. METOPROLOL**

C. PROPYLTHIOURACIL

D. RADIOACTIVE IODINE

# THYROIDITIS

- INFLAMMATION AND DESTRUCTION OF THE THYROID GLAND
  - RELEASE OF PERFORMED HORMONES INTO CIRCULATION
- MARKED BY SWOLLEN PAINFUL THYROID GLAND SEEN DURING THE ACUTE PHASE OF A VIRAL INFECTION OF THE THYROID GLAND
- FEVER, SORE THROAT, VOICE CHANGES, TREMOR, TACHYCARDIA AND OTHER SYMPATHOMIMETIC CHANGES ARE HALLMARKS.

De Quervain's Thyroiditis  
Silent or Painless Thyroiditis  
Direct Chemical Toxicity  
Radiation Thyroiditis  
Medications

- TREATMENT:
  - TRANSIENT AND IMPROVES ON ITS OWN
  - ANTI-THYROID MEDICATIONS ARE CONTRAINDICATED
  - BETA BLOCKERS & NSAIDS CAN BE USED FOR SYMPTOMATIC PATIENTS
    - GLUCOCORTICOIDS FOR SEVER CASES

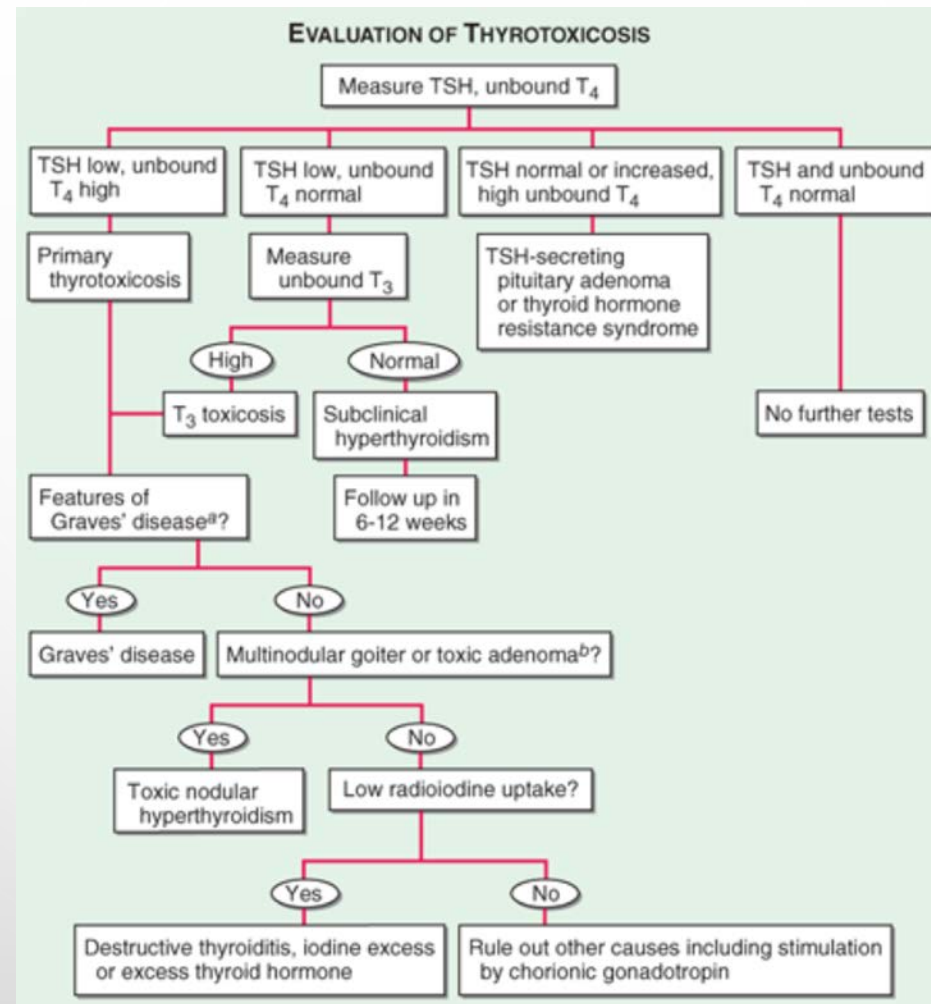
# QUESTION #3

- A 38-YEAR-OLD WOMAN IS EVALUATED BECAUSE OF A 3-WEEK HISTORY OF PALPITATIONS. SHE NOTES THAT HER HEART “RACES” AT NIGHT AND AFTER MINIMAL EXERTION. SHE ALSO REPORTS HEAT INTOLERANCE BUT HAS NO CHANGE IN BOWEL HABITS OR MENSES.
- PHYSICAL EXAMINATION
  - RESTLESS AND HAS PRESSURED SPEECH.
  - T - 36.8 °C (98.2 °F), BP - 130/60 MM HG, P - 110/MIN, RR - 12/MIN
  - SKIN IS WARM & MOIST
  - BILATERAL HAND TREMOR IS PRESENT
  - NO PROPTOSIS OR LID LAG
  - THYROID GLAND IS DIFFUSELY ENLARGED WITHOUT NODULES OR BRUITS
- LABORATORY EVALUATION
  - TSH: 0.08 MU/ML (0.08 MU/L)
  - FREE-T<sub>4</sub>: 1.7 NG/DL (21.9 PMOL/L)

## QUESTION #3 CONT.

- WHICH OF THE FOLLOWING IS THE MOST APPROPRIATE NEXT STEP IN MANAGEMENT?
  - A. MEASURE SERUM TRIIODOTHYRONINE (T3) LEVEL
  - B. MEASURE SERUM THYROID PEROXIDASE ANTIBODY TITER
  - C. REPEAT THYROID FUNCTION TESTS IN 6 WEEKS
  - D. SCHEDULE ULTRASOUND OF THE NECK





Evaluation of thyrotoxicosis. <sup>a</sup>Diffuse goiter, positive TPO antibodies, ophthalmopathy, dermopathy; <sup>b</sup>can be confirmed by radionuclide scan. TSH, thyroid-stimulating hormone.

# QUESTION #4

- A 64-YEAR-OLD MAN IN THE ICU IS EVALUATED BECAUSE OF ABNORMAL THYROID FUNCTION TESTS. HE WAS ADMITTED 3 DAYS AGO FOR COMMUNITY-ACQUIRED PNEUMONIA REQUIRING INTUBATION, MECHANICAL VENTILATION, INTRAVENOUS FLUIDS, AND DOPAMINE SUPPORT FOR HIS BLOOD PRESSURE.
- PHYSICAL EXAMINATION
  - RESTLESS AND HAS PRESSURED SPEECH.
  - T - 38.8 °C (101.8 °F), BP – 95/60 MM HG, P - 130/MIN
  - SKIN IS WARM & DRY
  - NO PROPTOSIS OR LID LAG
  - THYROID GLAND IS NORMAL SIZE AND TEXTURE WITHOUT NODULES OR BRUITS
  - CARDIOVASCULAR EXAMINATION REVEALS REGULAR TACHYCARDIA
  - BILATERAL PATELLAR AND ANKLE REFLEXES ARE SLIGHTLY DELAYED
- LABORATORY EVALUATION
  - TSH: 0.1 MU/ML (0.1 MU/L)
  - FREE-T<sub>4</sub>: 0.9 NG/DL (11.6 PMOL/L)
  - SERUM TOTAL T3: 50 NG/DL (0.8 NMOL/L)

# QUESTION #4

- A 64-YEAR-OLD MAN IN THE ICU IS EVALUATED BECAUSE OF ABNORMAL THYROID FUNCTION TESTS. HE WAS ADMITTED 3 DAYS AGO FOR COMMUNITY-ACQUIRED PNEUMONIA REQUIRING INTUBATION, MECHANICAL VENTILATION, INTRAVENOUS FLUIDS, AND DOPAMINE SUPPORT FOR HIS BLOOD PRESSURE.
- PHYSICAL EXAMINATION
  - RESTLESS AND HAS PRESSURED SPEECH.
  - T - 38.8 °C (101.8 °F), BP – 95/60 MM HG, P - 130/MIN
  - SKIN IS WARM & DRY
  - NO PROPTOSIS OR LID LAG
  - THYROID GLAND IS NORMAL SIZE AND TEXTURE WITHOUT NODULES OR BRUITS
  - CARDIOVASCULAR EXAMINATION REVEALS REGULAR TACHYCARDIA
  - BILATERAL PATELLAR AND ANKLE REFLEXES ARE SLIGHTLY DELAYED
- LABORATORY EVALUATION
  - TSH: 0.1 MU/ML (0.1 MU/L)
  - FREE-T<sub>4</sub>: 0.9 NG/DL (11.6 PMOL/L)
  - SERUM TOTAL T3: 50 NG/DL (0.8 NMOL/L)

WHICH OF THE FOLLOWING IS THE MOST LIKELY CAUSE OF THIS PATIENT'S ABNORMAL THYROID FUNCTION?

- A. EUTHYROID SICK SYNDROME
- B. GRAVES DISEASE
- C. HASHIMOTO THYROIDITIS
- D. SUBACUTE THYROIDITIS

# QUESTION #4

- A 64-YEAR-OLD MAN IN THE ICU IS EVALUATED BECAUSE OF ABNORMAL THYROID FUNCTION TESTS. HE WAS ADMITTED 3 DAYS AGO FOR COMMUNITY-ACQUIRED PNEUMONIA REQUIRING INTUBATION, MECHANICAL VENTILATION, INTRAVENOUS FLUIDS, AND DOPAMINE SUPPORT FOR HIS BLOOD PRESSURE.
- PHYSICAL EXAMINATION
  - RESTLESS AND HAS PRESSURED SPEECH.
  - T - 38.8 °C (101.8 °F), BP – 95/60 MM HG, P - 130/MIN
  - SKIN IS WARM & DRY
  - NO PROPTOSIS OR LID LAG
  - THYROID GLAND IS NORMAL SIZE AND TEXTURE WITHOUT NODULES OR BRUITS
  - CARDIOVASCULAR EXAMINATION REVEALS REGULAR TACHYCARDIA
  - BILATERAL PATELLAR AND ANKLE REFLEXES ARE SLIGHTLY DELAYED
- LABORATORY EVALUATION
  - TSH: 0.1 MU/ML (0.1 MU/L)
  - FREE-T<sub>4</sub>: 0.9 NG/DL (11.6 PMOL/L)
  - SERUM TOTAL T3: 50 NG/DL (0.8 NMOL/L)

WHICH OF THE FOLLOWING IS THE MOST LIKELY CAUSE OF THIS PATIENT'S ABNORMAL THYROID FUNCTION?

**A. EUTHYROID SICK SYNDROME**

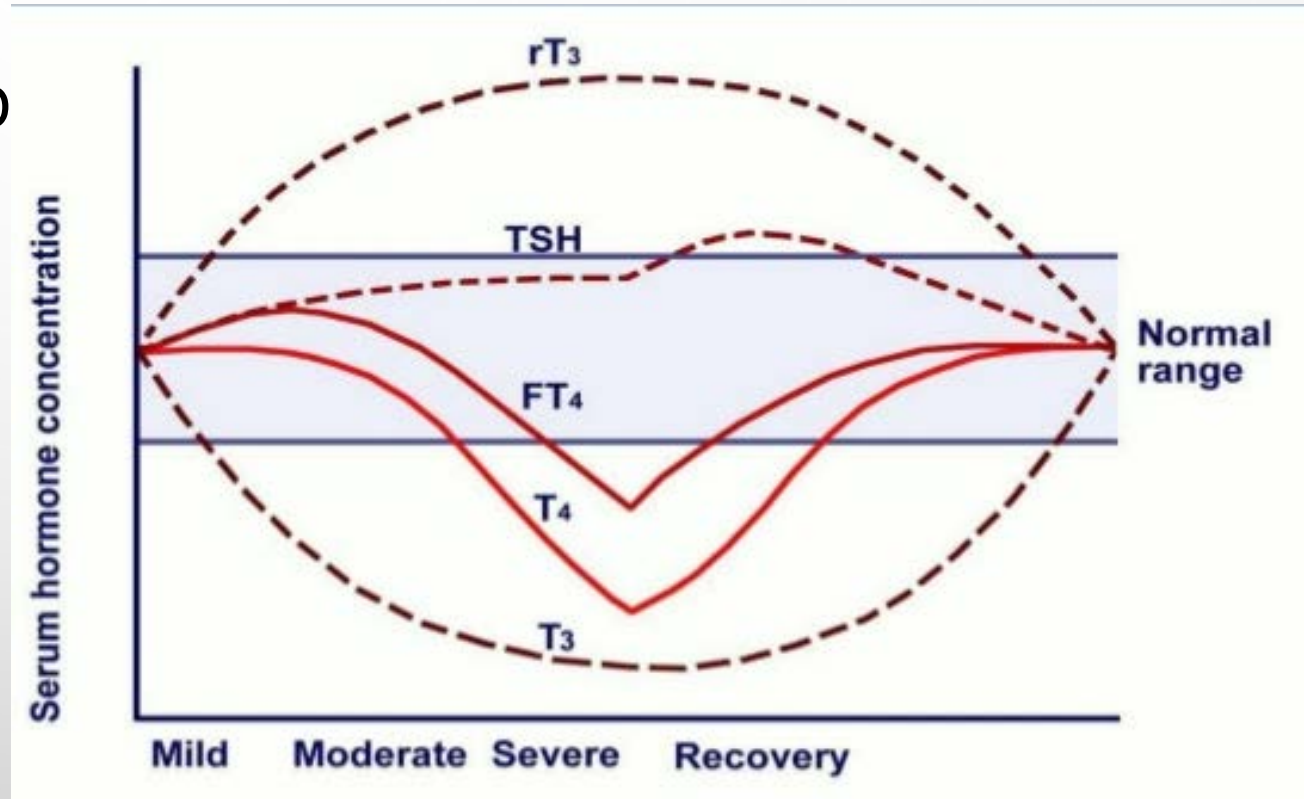
B. GRAVES DISEASE

C. HASHIMOTO THYROIDITIS

D. SUBACUTE THYROIDITIS

# EUTHYROID SICK SYNDROME (NONTHYROIDAL ILLNESS SYNDROME)

- THYROID FUNCTION TESTS SHOULD NOT BE ORDERED DURING A CRITICAL ILLNESS.
- CRITICAL ILLNESS
  - LOW TOTAL TRIIODOTHYRONINE (T3) LEVEL
  - PROGRESSION OF SEVERITY OF ILLNESS
    - LOW TSH & FREE THYROXINE (T4) LEVELS



# QUESTION #5

- 27-YEAR-OLD FEMALE PRESENTS FOR PRE-CONCEPTION COUNSELING. HER ONLY COMPLAINT IS SWELLING IN HER NECK. HER MOTHER AND SISTER HAVE HYPOTHYROIDISM.
- PHYSICAL EXAM
  - ALERT AND ORIENTED
  - VITAL SIGNS ARE NORMAL
  - THYROID GLAND IS DIFFUSELY ENLARGED AND SMOOTH. NO DISCRETE NODULE PALPATED.
  - NO EXOPHTHALMOS
  - NO PRETIBIAL MYXEDEMA
- LABORATORY EVALUATION
  - TSH: 6.5 MU/ML
  - FREE-T<sub>4</sub>: 1.0 NG/DL
  - TPO ANTIBODY POSITIVE



# QUESTION #5

- 27-YEAR-OLD FEMALE PRESENTS FOR PRE-CONCEPTION COUNSELING. HER ONLY COMPLAINT IS SWELLING IN HER NECK. HER MOTHER AND SISTER HAVE HYPOTHYROIDISM.
- PHYSICAL EXAM
  - ALERT AND ORIENTED
  - VITAL SIGNS ARE NORMAL
  - THYROID GLAND IS DIFFUSELY ENLARGED AND SMOOTH. NO DISCRETE NODULE PALPATED.
  - NO EXOPHTHALMOS
  - NO PRETIBIAL MYXEDEMA
- LABORATORY EVALUATION
  - TSH: 6.5 MU/ML
  - FREE-T<sub>4</sub>: 1.0 NG/DL
  - TPO ANTIBODY POSITIVE

WHAT IS THE BEST NEXT STEP IN MANAGEMENT?

- A. THYROID UPTAKE AND SCAN
- B. LEVOTHYROXINE TREATMENT
- C. THYROID BIOPSY
- D. REPEAT TSH IN 3 MONTHS
- E. LIOTHYRONINE TREATMENT

# QUESTION #5

- 27-YEAR-OLD FEMALE PRESENTS FOR PRE-CONCEPTION COUNSELING. HER ONLY COMPLAINT IS SWELLING IN HER NECK. HER MOTHER AND SISTER HAVE HYPOTHYROIDISM.
- PHYSICAL EXAM
  - ALERT AND ORIENTED
  - VITAL SIGNS ARE NORMAL
  - THYROID GLAND IS DIFFUSELY ENLARGED AND SMOOTH. NO DISCRETE NODULE PALPATED.
  - NO EXOPHTHALMOS
  - NO PRETIBIAL MYXEDEMA
- LABORATORY EVALUATION
  - TSH: 6.5 MU/ML
  - FREE-T<sub>4</sub>: 1.0 NG/DL
  - TPO ANTIBODY POSITIVE

WHAT IS THE BEST NEXT STEP IN MANAGEMENT?

- A. THYROID UPTAKE AND SCAN
- B. LEVOTHYROXINE TREATMENT**
- C. THYROID BIOPSY
- D. REPEAT TSH IN 3 MONTHS
- E. LIOTHYRONINE TREATMENT

# HYPOTHYROIDISM – CLINICAL PRESENTATION

Mechanism	Symptoms	Signs
Slowing of Metabolic Process	Fatigue & Weakness Cold Intolerance Dyspnea on Exertion Weight Gain Cognitive Dysfunction Mental Retardation (infantile onset) Constipation Growth Failure	Slow Movement & Slow Speech Delayed Relaxation of Tendon Reflexes Bradycardia Carotenemia
Accumulation of Matrix Substances	Dry Skin Hoarseness Edema	Coarse Skin Puffy Face & Loss of Eyebrows Periorbital Edema Enlargement of the Tongue Carpal Tunnel Syndrome
Other	Decreased Hearing Myalgia & Paresthesia Depression Menorrhagia Arthralgia Pubertal Delay	Diastolic Hypertension Pleural & Pericardial Effusions Ascites Galactorrhea

# HYPOTHYROIDISM – ETIOLOGY

## PRIMARY HYPOTHYROIDISM

- CHRONIC AUTOIMMUNE THYROIDITIS
- IATROGENIC
  - THYROIDECTOMY
  - RADIOIODINE THERAPY OR EXTERNAL IRRADIATION
- IODINE DEFICIENCY OR EXCESS
- DRUGS
- INFILTRATIVE DISEASE
  - FIBROUS THYROIDITIS, HEMOCHROMATOSIS, SARCOIDOSIS
- TRANSIENT HYPOTHYROIDISM
  - PAINLESS (SILENT, LYMPHOCYTIC) THYROIDITIS, SUBACUTE GRANULOMATOUS THYROIDITIS, POSTPARTUM THYROIDITIS, SUBTOTAL THYROIDECTOMY
  - FOLLOWING RADIOIODINE THERAPY FOR GRAVES' HYPERTHYROIDISM
  - FOLLOWING WITHDRAWAL OF SUPPRESSIVE DOSES OF THYROID HORMONE IN EUTHYROID PATIENTS
- CONGENITAL THYROID AGENESIS, DYSGENESIS, OR DEFECTS IN HORMONE SYNTHESIS

## CENTRAL HYPOTHYROIDISM

- TSH DEFICIENCY
- TRH DEFICIENCY

## Generalized Thyroid Hormone Resistance

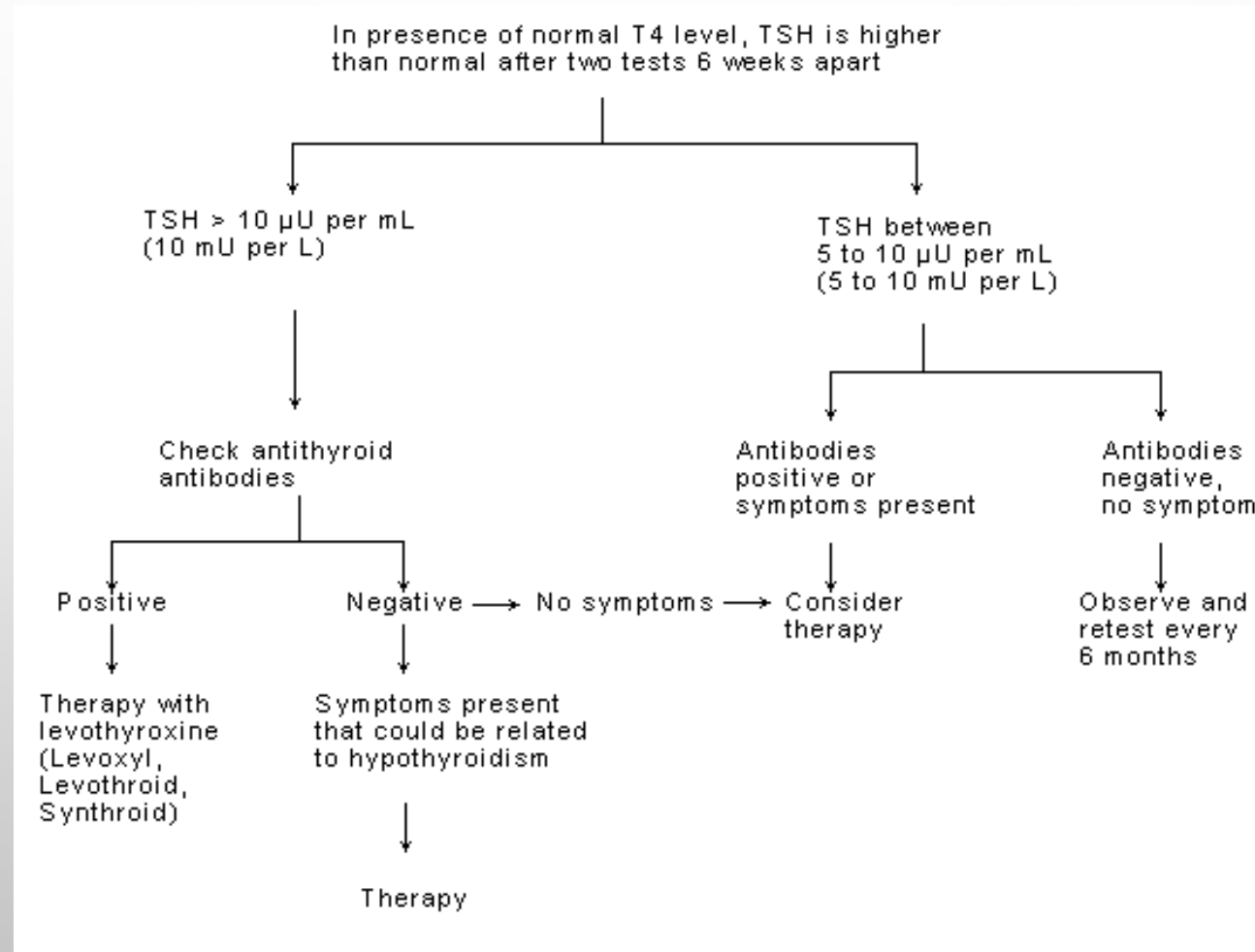
Thionamides  
Lithium  
Amiodarone  
Interferon-alfa  
Interleukin-2  
Tyrosine Kinase

Inhibitors  
Checkpoint inhibitor  
immunotherapy  
Fluoride  
Amionsalicylic acid  
Phenylbutazone

# SUBCLINICAL HYPOTHYROIDISM

- ELEVATED SERUM TSH; NORMAL FREE T4
  - +/- SYMPTOMS
  - IF TSH < 10, WILL OFTEN NORMALIZE ON REPEAT MEASUREMENT
  - BENEFIT OF TREATMENT IS NOT CLEAR
    - MAY IMPROVE SYMPTOMS
    - MAY IMPROVE LIPIDS
  - IF TPO AB+, MAY PREDICT BETTER RESPONSE TO TREATMENT
- INDICATIONS FOR TREATMENT
    - SYMPTOMATIC PATIENT
    - TSH > 10
    - TPO AB POSITIVE
    - PREGNANT OR TRYING TO BECOME PREGNANT
    - YOUNGER PATIENTS
    - POSSIBLY HYPERLIPIDEMIC PATIENT

# SUBCLINICAL HYPOTHYROIDISM



# HASHIMOTO THYROIDITIS (CHRONIC AUTOIMMUNE THYROIDITIS)

- **MCC OF HYPOTHYROIDISM**
- 7:1 FEMALE TO MALE
- MCC OF HYPOTHYROIDISM IN CHILDREN
- INFLAMMATORY PROCESS IN DISEASE CAN CAUSE A TRANSIENT HYPERTHYROIDISM

# HASHIMOTO THYROIDITIS (CHRONIC AUTOIMMUNE THYROIDITIS)

- PATHOPHYSIOLOGY – AUTOIMMUNE MEDIATED DESTRUCTION WITH APOPTOSIS OF THYROID EPITHELIAL CELLS
  - LYMPHOCYTIC INFILTRATION, FIBROSIS AND THYROID FOLLICULAR CELL HYPERPLASIA
- GENETIC SUSCEPTIBILITY
  - FAMILY CLUSTERS
  - INCREASED INCIDENCE IN PATIENTS WITH HISTORY OF OTHER AUTOIMMUNE DISEASES
- TRIGGERS - INFECTION, METABOLIC STRESS, ENVIRONMENTAL (TOBACCO, IONIZING RADIATION), DIETARY (EXCESS IODINE INGESTION)



# HASHIMOTO THYROIDITIS (CHRONIC AUTOIMMUNE THYROIDITIS)

- AUTOANTIBODIES
  - THYROID PEROXIDASE (TPO) (90-95% OF PATIENTS)
  - THYROGLOBULIN (TG) (70-75% OF PATIENTS)
  - TSH RECEPTOR BLOCKER ANTIBODY (20-25% OF PATIENTS)
- FIX COMPLEMENT, DIRECT CYTOLYSIS → CYTOTOXICITY & THYROID DESTRUCTION
  - 11-18% OF EUTHYROID WOMEN TEST POSITIVE FOR THESE ANTIBODIES
- HASHIMOTO DISEASE: TSH ANTIBODIES BLOCK THE ACTION OF TSH
- GRAVES DISEASE: TSH ANTIBODIES ACTIVATE TSH ACTION

# HASHIMOTO ENCEPHALOPATHY

- IMMUNE MEDIATED
  - ANTIBODY DIRECTED NEURONAL INJURY
- PRESENTATION
  - CONFUSION, ALTERED LEVEL OF CONSCIOUSNESS, SEIZURE, AND MYOCLONUS
- MANAGEMENT
  - HIGH DOSE STEROID THERAPY
    - 98% RESPONSE RATE
  - OTHER CONSIDERATIONS: AZATHIOPRINE AND CYCLOPHOSPHAMIDE

# TREATMENT OF HYPOTHYROIDISM

- TREATMENT SHOULD BE WITH PO LEVOTHYROXINE
- STARTING DOSE INDIVIDUALIZED
- SEVERE HYPOTHYROIDISM AND NO CARDIOVASCULAR DISEASE – 1.6MCG/KG STARTING DOSE
- MILD HYPOTHYROIDISM OR PATIENT WITH CARDIOVASCULAR DISEASE – 25 MCG/DAY
  - START LOW AND INCREASE SLOW
- MEASURE TSH AND FREE T4 AT 4-6 WEEK INTERVALS
  - TITRATE TO KEEP TSH IN NORMAL RANGE
- MEDICATIONS THAT INTERFERE WITH ABSORPTION OF THYROID HORMONE

Calcium

Iron

Proton Pump

Inhibitors

Antacids

Sucralfate

Carbamazepine

Phenytoin

Phenobarbital

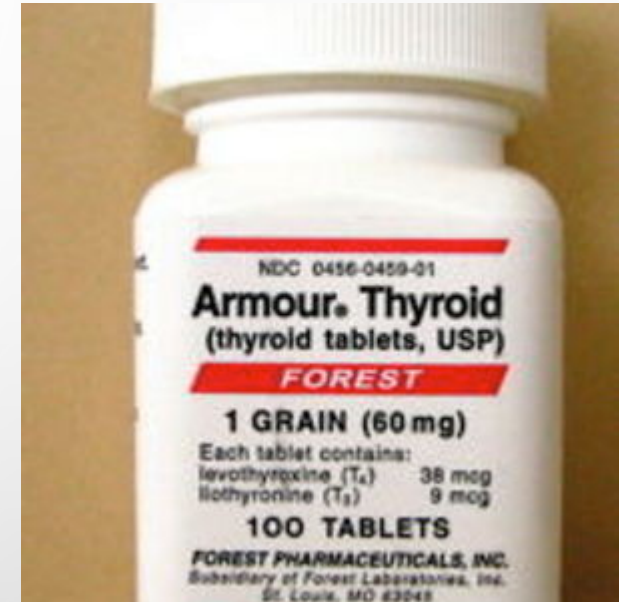Ciprofloxin

Rifampin

- TAKE THYROID HORMONE ON AN EMPTY STOMACH

# WHY NOT TRIIODOTHYRONINE (T3)?

- DESICCATED THYROID
  - VARIATION IN POTENCY AND BIOAVAILABILITY OF DESICCATED THYROID PROVIDE INCONSISTENT HORMONE LEVELS
  - SHORT  $\frac{1}{2}$  LIFE (~12 HOURS) AND VARIABLE GI ABSORPTION OF T3 LEADING TO FLUCTUATIONS IN SERUM T3 CONCENTRATION



Synthetic Thyroxine (T4)  
 $\frac{1}{2}$  Life: 6 - 7 days  
80% absorbed from GI tract

# TREATMENT OF HYPOTHYROIDISM IN PREGNANCY

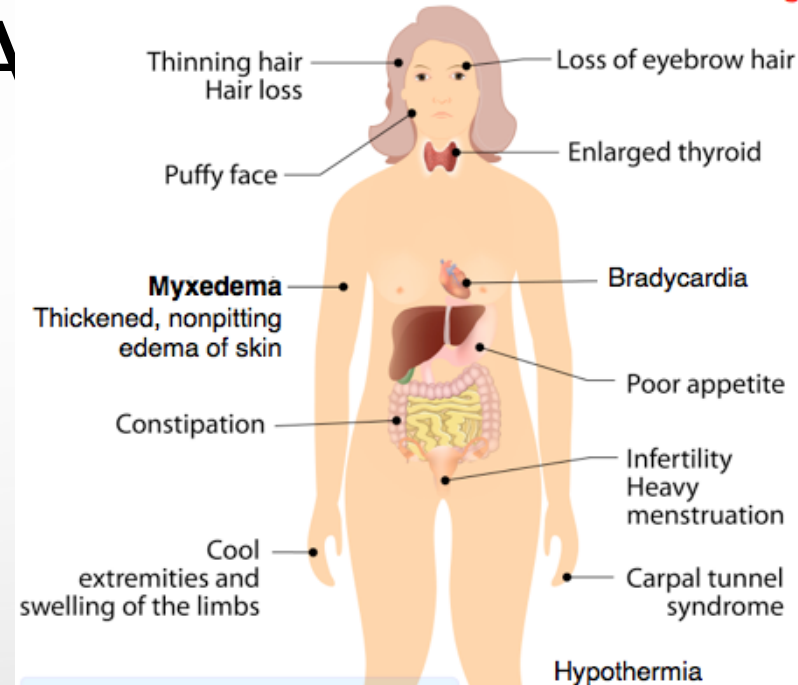
- PATIENT ON THYROID REPLACEMENT THERAPY WHO GET PREGNANT
  - INCREASE REPLACEMENT DOSE BY 30%
    - MAY REQUIRE UP TO A 45% INCREASE IN DOSE BY END OF SECOND TRIMESTER
  - CHECK TSH EACH TRIMESTER
- PATIENTS WITH SUBCLINICAL HYPOTHYROIDISM & THYROID PEROXIDASE ANTIBODY
  - START ON THYROID REPLACEMENT THERAPY
- WOMEN ON THYROID REPLACEMENT THERAPY AND START ESTROGEN REPLACEMENT THERAPY
  - CHECK TSH IN 12 WEEKS AFTER INITIATION
    - LIKELY WILL NEED INCREASE DOSE OF THYROID REPLACEMENT MEDICATIONS

# MYXEDEMA

- MORTALITY RATE APPROACHES 80%
- TREATMENT IV GLUCOCORTICOID & SYNTHETIC THYROID HORMONE
- CRITICAL CARE MANAGEMENT – AIRWAY, REWARMING, FLUID STATUS, ELECTROLYTE ABNORMALITIES
- TREAT UNDERLYING MEDICAL ISSUES

## Myxedema Coma

Severe **hypothyroidism** resulting in a decompensated metabolic state and **mental status change**



### Precipitating factors

- Infection
- Cold exposure
- Stroke
- Meds (amiodarone, lithium)

### Laboratory findings

- Hypoglycemia, Hyponatremia
- Hypoxemia, hypercapnea
- Prolonged QT, low voltage
- Pericardial effusion

### Management

- Supportive (airway, rewarming)
- Hydrocortisone
- Levothyroxine (T4)
- +/- T3 supplementation

# QUESTION #6

- AN 84-YEAR-OLD MAN IS EVALUATED FOR MODERATE FATIGUE. HE OTHERWISE FEELS WELL AND DOES NOT HAVE CONSTIPATION, COLD INTOLERANCE, WEIGHT GAIN OR LOSS, ANXIETY, TREMOR, PALPITATIONS, OR DYSPNEA. MEDICAL HISTORY IS SIGNIFICANT FOR HYPERTENSION, AND HIS ONLY MEDICATION IS FELODIPINE.
- PHYSICAL EXAM
  - ALERT AND ORIENTED
  - BP - 144/83 MM HG; OTHER VITAL SIGNS ARE NORMAL
  - THYROID GLAND IS NOT PALPABLE
  - CARDIOPULMONARY EXAMINATION IS NORMAL
  - NO PERIPHERAL EDEMA
  - NEUROLOGIC EXAMINATION IS NONFOCAL; DTR ARE NORMAL
- LABORATORY EVALUATION
  - CBC – NORMAL
  - CMP – NORMAL
  - TSH – 6.4 MU/ML (6.4 MU/L)
  - FREE T4 – 1.3 NG/DL (16.8 PMOL/L)

- AN 84-YEAR-OLD MAN IS EVALUATED FOR MODERATE FATIGUE. HE OTHERWISE FEELS WELL AND DOES NOT HAVE CONSTIPATION, COLD INTOLERANCE, WEIGHT GAIN OR LOSS, ANXIETY, TREMOR, PALPITATIONS, OR DYSPNEA. MEDICAL HISTORY IS SIGNIFICANT FOR HYPERTENSION, AND HIS ONLY MEDICATION IS FELODIPINE.
- PHYSICAL EXAM
  - ALERT AND ORIENTED
  - BP - 144/83 MM HG; OTHER VITAL SIGNS ARE NORMAL
  - THYROID GLAND IS NOT PALPABLE
  - CARDIOPULMONARY EXAMINATION IS NORMAL
  - NO PERIPHERAL EDEMA
  - NEUROLOGIC EXAMINATION IS NONFOCAL; DTR ARE NORMAL
- LABORATORY EVALUATION
  - CBC – NORMAL
  - CMP – NORMAL
  - TSH – 6.4 MU/ML (6.4 MU/L)
  - FREE T4 – 1.3 NG/DL (16.8 PMOL/L)

## QUESTION #6

- WHICH OF THE FOLLOWING IS THE MOST APPROPRIATE MANAGEMENT?
  - A. LEVOTHYROXINE THERAPY
  - B. MEASUREMENT OF SERUM TOTAL TRIIODOTHYRONINE (T3) LEVEL
  - C. MEASUREMENT OF SERUM TOTAL T4 LEVEL
  - D. REPEAT TSH AND FREE T4 MEASUREMENT IN 6 TO 12 WEEKS



# QUESTION #6

- AN 84-YEAR-OLD MAN IS EVALUATED FOR MODERATE FATIGUE. HE OTHERWISE FEELS WELL AND DOES NOT HAVE CONSTIPATION, COLD INTOLERANCE, WEIGHT GAIN OR LOSS, ANXIETY, TREMOR, PALPITATIONS, OR DYSPNEA. MEDICAL HISTORY IS SIGNIFICANT FOR HYPERTENSION, AND HIS ONLY MEDICATION IS FELODIPINE.
- PHYSICAL EXAM
  - ALERT AND ORIENTED
  - BP - 144/83 MM HG; OTHER VITAL SIGNS ARE NORMAL
  - THYROID GLAND IS NOT PALPABLE
  - CARDIOPULMONARY EXAMINATION IS NORMAL
  - NO PERIPHERAL EDEMA
  - NEUROLOGIC EXAMINATION IS NONFOCAL; DTR ARE NORMAL
- LABORATORY EVALUATION
  - CBC – NORMAL
  - CMP – NORMAL
  - TSH – 6.4 MU/ML (6.4 MU/L)
  - FREE T4 – 1.3 NG/DL (16.8 PMOL/L)

- WHICH OF THE FOLLOWING IS THE MOST APPROPRIATE MANAGEMENT?

A. LEVOTHYROXINE THERAPY

B. MEASUREMENT OF SERUM TOTAL TRIIODOTHYRONINE (T3) LEVEL

C. MEASUREMENT OF SERUM TOTAL T4 LEVEL

**D. REPEAT TSH AND FREE T4 MEASUREMENT IN 6 TO 12 WEEKS**

# QUESTION #7

- 35-YEAR-OLD MALE PRESENTS FOR EVALUATION OF A “LUMP” THAT HE NOTICED IN HIS NECK WHILE SHAVING. HE HAS NO OTHER COMPLAINTS.
- PHYSICAL EXAM
  - ALERT AND ORIENTED
  - VITAL SIGNS ARE NORMAL
  - THYROID GLAND HAS A 3 CM SOLITARY FIRM, MOBILE, PAINLESS NODULE IN THE RIGHT THYROID LOBE.
  - NO TRACHEAL DEVIATION.
- LABORATORY EVALUATION
  - TSH: 2.2 MU/ML

# QUESTION #7

- 35-YEAR-OLD MALE PRESENTS FOR EVALUATION OF A “LUMP” THAT HE NOTICED IN HIS NECK WHILE SHAVING. HE HAS NO OTHER COMPLAINTS.
- PHYSICAL EXAM
  - ALERT AND ORIENTED
  - VITAL SIGNS ARE NORMAL
  - THYROID GLAND HAS A 3 CM SOLITARY FIRM, MOBILE, PAINLESS NODULE IN THE RIGHT THYROID LOBE.
  - NO TRACHEAL DEVIATION.
- LABORATORY EVALUATION
  - TSH: 2.2 MU/ML

WHAT CHARACTERISTIC DOES NOT INCREASE THE LIKELIHOOD OF MALIGNANCY OF THE NODULE?

- A. SIZE GREATER THAN 1 CM
- B. FAMILY HISTORY OF THYROID CANCER
- C. POSITIVE UPTAKE ON PET SCANNING
- D. LOW TSH
- E. HISTORY OF TOTAL BODY IRRADIATION FOR BONE MARROW TRANSPLANTATION

# QUESTION #7

- 35-YEAR-OLD MALE PRESENTS FOR EVALUATION OF A “LUMP” THAT HE NOTICED IN HIS NECK WHILE SHAVING. HE HAS NO OTHER COMPLAINTS.
- PHYSICAL EXAM
  - ALERT AND ORIENTED
  - VITAL SIGNS ARE NORMAL
  - THYROID GLAND HAS A 3 CM SOLITARY FIRM, MOBILE, PAINLESS NODULE IN THE RIGHT THYROID LOBE.
  - NO TRACHEAL DEVIATION.
- LABORATORY EVALUATION
  - TSH: 2.2 MU/ML

WHAT CHARACTERISTIC DOES NOT INCREASE THE LIKELIHOOD OF MALIGNANCY OF THE NODULE?

- A. SIZE GREATER THAN 1 CM
- B. FAMILY HISTORY OF THYROID CANCER
- C. POSITIVE UPTAKE ON PET SCANNING
- D. LOW TSH**
- E. HISTORY OF TOTAL BODY IRRADIATION FOR BONE MARROW TRANSPLANTATION

# THYROID NODULE EPIDEMIOLOGY

## Prevalence of thyroid nodules

Palpable on exam  
1-5% women > men

Seen on ultrasound  
19-67%

# ETIOLOGY OF THYROID NODULES

## BENIGN

- MULTINODULAR (SPORADIC) GOITER (“COLLOID ADENOMA”)
- HASHIMOTO’S (CHRONIC LYMPHOCYTIC) THYROIDITIS
- CYSTS (COLLOID, SIMPLE, OR HEMORRHAGIC)
- FOLLICULAR ADENOMAS
  - MACROFOLLICULAR ADENOMAS
  - MICROFOLLICULAR OR CELLULAR ADENOMAS
- HURTHLE CELL (OXYPHIL CELL) ADENOMAS
  - MACRO- OR MICROFOLLICULAR PATTERNS

## MALIGNANT

- PAPILLARY CARCINOMA
- FOLLICULAR CARCINOMA
  - MINIMALLY OR WIDELY INVASIVE
  - OXYPHILIC (HURTHLE CELL) TYPE
  - NONINVASIVE FOLLICULAR THYROID NEOPLASM WITH PAPILLARY-LIKE NUCLEAR FEATURES
- MEDULLARY CARCINOMA
- ANAPLASTIC CARCINOMA
- PRIMARY THYROID LYMPHOMA

# ETIOLOGY OF THYROID NODULES


## BENIGN

- MULTINODULAR (SPORADIC) GOITER ("COLLOID ADENOMA")
- HASHIMOTO'S (CHRONIC LYMPHOCYTIC) THYROIDITIS
- CYSTS (COLLOID, SIMPLE, OR HEMORRHAGIC)
- FOLLICULAR ADENOMAS
  - MACROFOLLICULAR ADENOMAS
  - MICROFOLLICULAR OR CELLULAR ADENOMAS
- HURTHLE CELL (OXYPHIL CELL) ADENOMAS
  - MACRO- OR MICROFOLLICULAR PATTERNS

## MALIGNANT

- PAPILLARY CARCINOMA
- FOLLICULAR CARCINOMA
  - MINIMALLY OR WIDELY INVASIVE
  - OXYPHILIC (HURTHLE CELL) TYPE
  - NONINVASIVE FOLLICULAR THYROID NEOPLASM WITH PAPILLARY-LIKE NUCLEAR FEATURES
- MEDULLARY CARCINOMA
- ANAPLASTIC CARCINOMA

5-15% of nodules are thyroid cancer  
Risk factors: age, sex, XRT exposure, FHx



90% of thyroid ca are differentiated thyroid ca  
Papillary or follicular  
• METASTATIC CARCINOMA (BREAST, RENAL CELL, OTHERS)

# QUESTION #7

- 35-YEAR-OLD MALE PRESENTS FOR EVALUATION OF A “LUMP” THAT HE NOTICED IN HIS NECK WHILE SHAVING. HE HAS NO OTHER COMPLAINTS.
- PHYSICAL EXAM
  - ALERT AND ORIENTED
  - VITAL SIGNS ARE NORMAL
  - THYROID GLAND HAS A 3 CM SOLITARY FIRM, MOBILE, PAINLESS NODULE IN THE RIGHT THYROID LOBE.
  - NO TRACHEAL DEVIATION.
- LABORATORY EVALUATION
  - TSH: 2.2 MU/ML

WHAT IS THE MOST APPROPRIATE NEXT STEP IN THE EVALUATION OF THIS PATIENT?

- A. COMPUTED TOMOGRAPHY OF THE NECK
- B. THYROID UPTAKE AND SCAN
- C. FINE-NEEDLE ASPIRATION
- D. PET SCAN
- E. BARIUM SWALLOW



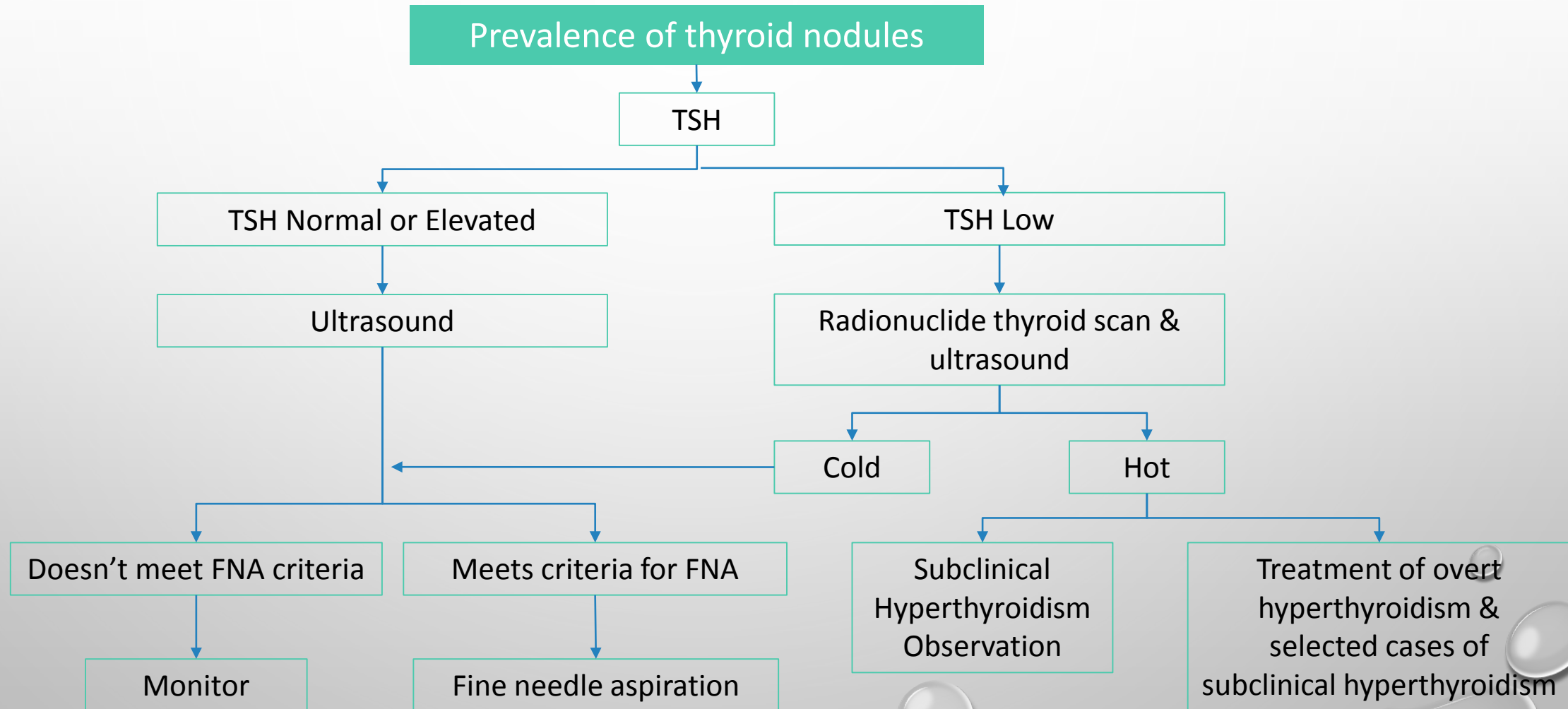
# QUESTION #7

- 35-YEAR-OLD MALE PRESENTS FOR EVALUATION OF A “LUMP” THAT HE NOTICED IN HIS NECK WHILE SHAVING. HE HAS NO OTHER COMPLAINTS.
- PHYSICAL EXAM
  - ALERT AND ORIENTED
  - VITAL SIGNS ARE NORMAL
  - THYROID GLAND HAS A 3 CM SOLITARY FIRM, MOBILE, PAINLESS NODULE IN THE RIGHT THYROID LOBE.
  - NO TRACHEAL DEVIATION.
- LABORATORY EVALUATION
  - TSH: 2.2 MU/ML

WHAT IS THE MOST APPROPRIATE NEXT STEP IN THE EVALUATION OF THIS PATIENT?

- A. COMPUTED TOMOGRAPHY OF THE NECK
- B. THYROID UPTAKE AND SCAN
- C. FINE-NEEDLE ASPIRATION**
- D. PET SCAN
- E. BARIUM SWALLOW

# THYROID NODULE EVALUATION



# ULTRASOUND FEATURES THE REQUIRE FNA

- GENERAL RULES:
  - MOST NODULES > 1 CM SHOULD HAVE FNA
  - HOT NODULES ARE ALMOST ALWAYS BENIGN
  - RISK FACTORS FOR THYROID CANCER:
    - FAMILY HISTORY
    - PRIOR RADIATION THERAPY

## Ultrasonographic features that are associated with an increased risk of thyroid cancer

Hypoechoic

Microcalcifications

“Twinkling” on B-flow imaging

Central vascularity

Irregular margins

Incomplete halo

Nodule is taller than wide

Documented enlargement of a nodule

## Ultrasonographic features that are associated with low risk of thyroid cancer

Hyperechoic


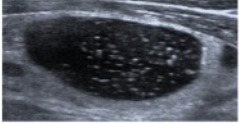
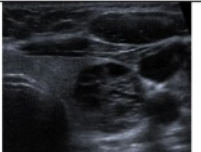
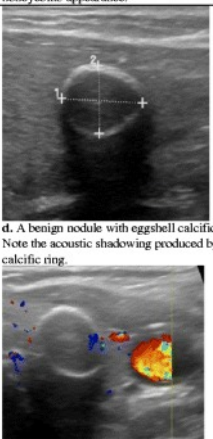

Large, coarse calcifications (except medullary ca)

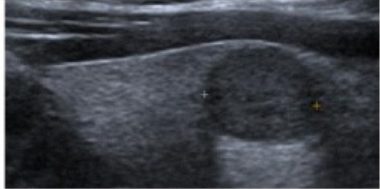
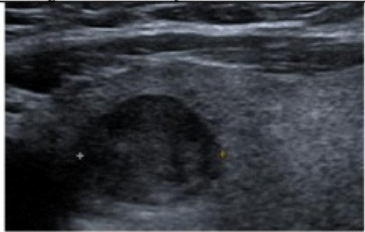

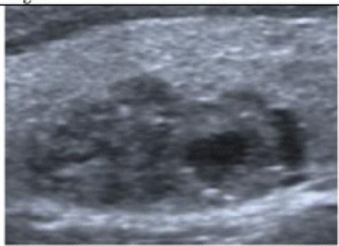
Peripheral vascularity

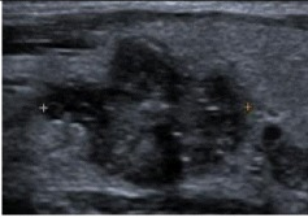

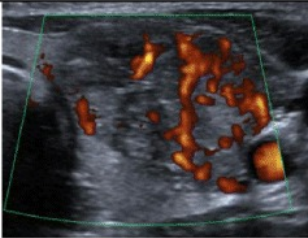

Resembles puff or Napoleon pastry

Spongiform appearance

Comet-tail shadowing

BTA U-classification	Thyroid ultrasound & description	Fine needle aspiration cytology (FNAC)
U2 (a) – Benign: halo, iso-echoic / mildly hyper-echoic	 a. A benign nodule. It is iso-echoic relative to the thyroid, and surrounded by a hypoechoic halo.	Not required*
U2 (b) – Benign: cystic change +/- ring down sign (colloid)	 b. A benign cystic nodule with multiple colloids, which are seen as hyper-echoic spots with comet-tail.	Not required*
U2 (c) – Benign: Micro-cystic / spongiform	 c. A benign nodule with hypo-echoic cystic spaces resulting in a spongiform or honeycomb appearance.	Not required*
U2 (d & e) – Benign: Peripheral egg shell calcification	 d. A benign nodule with eggshell calcification. Note the acoustic shadowing produced by the calcific ring. e. A benign nodule with eggshell calcification.	Not required*
U2 (f) – Benign: Peripheral vascularity	 f. A benign nodule with peripheral vascularity on doppler assessment.	Not required*

BTA U-classification	Thyroid ultrasound & description	Fine needle aspiration cytology (FNAC)
U4 (a) – Suspicious: Solid, hypo-echoic (cf thyroid)	 a. A suspicious hypo-echoic nodule with signal lower than the surrounding thyroid tissue but higher than the strap muscle above.	Required
U4 (b) – Suspicious: Solid, very hypo-echoic (cf strap muscle)	 b. A suspicious hypo-echoic nodule with signal lower than both thyroid tissue and strap muscle.	Required
U4 (c) – Suspicious: Disrupted peripheral calcification, hypo-echoic	 c. A suspicious hypo-echoic nodule with interrupted eggshell calcification around the edges.	Required
U4 (d) – Suspicious: Lobulated outline	 d. A suspicious hypo-echoic nodule with a lobular margin.	Required

BTA U-classification	Thyroid ultrasound & description	Fine needle aspiration cytology (FNAC)
U5 (a) – Malignant: Solid, hypo-echoic, lobulated / irregular outline, micro-calcification (?Papillary carcinoma)	 a. This hypo-echoic nodule has small hyper-echoic foci of calcification and an irregular lobulated contour. FNAC confirmed papillary thyroid cancer.	Required
U5 (b) – Malignant: Solid, hypo-echoic, lobulated / irregular outline, globular calcification (?Medullary carcinoma)	 b. This hypo-echoic nodule has a single coarse globular calcification and an irregular contour. FNAC confirmed medullary thyroid cancer.	Required
U5 (c) – Malignant: Intra-nodular vascularity	 c. Thyroid nodule with intra-nodular vascularity. Later confirmed to be papillary thyroid cancer.	Required
U5 (d) – Malignant: Shape (taller > wide)	 d. A hypo-echoic nodule that is taller than wide is considered to be malignant.	Required

# SUMMARY THYROID NODULES

- THYROID NODULES ARE COMMON INCIDENTAL FINDING
  - 10-30% MEN; 20-50% WOMEN; INCREASE WITH AGE
- APPROXIMATELY 5-15% ARE MALIGNANT
- INITIAL ASSESSMENT – TSH AND THYROID ULTRASOUND
- RAI SCAN INDICATED ONLY IF TSH IS SUPPRESSED
- FNA IS THE MOST ACCURATE AND COST-EFFECTIVE WAY OF EVALUATING THYROID NODULES
- DECISION FOR FNA SHOULD BE BASED ON SONOGRAPHIC CHARACTERISTICS OF NODULES AND ASSESSMENT OF PATIENT RISK FACTORS FOR MALIGNANCY

# SUMMARY

## Normal hypothalamic-pituitary function

Serum TSH	Serum T4	Serum T3	Assessment
Normal	Normal	Normal	Euthyroid
Normal	Normal or high	Normal or high	Euthyroid hyperthyroxinemia
Normal	Normal or low	Normal or low	Euthyroid hypothyroxinemia
Normal	Low	Normal or high	Euthyroid: T3 therapy
Normal	Low-normal or low	Normal or high	Euthyroid: thyroid extract therapy
High	Low	Normal or low	Primary hypothyroidism
High	Normal	Normal	Subclinical hypothyroidism
Low	High or normal	High	Hyperthyroidism
Low	Normal	Normal	Subclinical hyperthyroidism

# SUMMARY

## Abnormal hypothalamic-pituitary function

Serum TSH	Serum T4	Serum T3	Assessment
Normal or high	High	High	TSH-mediated hyperthyroidism
Normal or low	Low or low-normal	Low or normal	Central hypothyroidism

# REFERENCES

- ADLIN V. SUBCLINICAL HYPOTHYROIDISM: DECIDING WHEN TO TREAT. AM FAM PHYSICIAN. 1995 FEB 15. 57(4): 776-80.
- FARWELL AP. NONTHYROIDAL ILLNESS SYNDROME. CURR OPIN ENDOCRINOL DIABETES OBES. 2013 OCT;20(5):478-84. [PMID: 23974778](#)
- COOPER DS, ET AL. AMERICAN THYROID ASSOCIATION (ATA) GUIDELINES TASKFORCE ON THYROID NODULES AND DIFFERENTIATED THYROID CANCER. REVISED AMERICAN THYROID ASSOCIATION MANAGEMENT GUIDELINES FOR PATIENTS WITH THYROID NODULES AND DIFFERENTIATED THYROID CANCER [PUBLISHED CORRECTIONS APPEAR IN THYROID. 2010;20(6):674–675.
- GARBER JR ET AL. CLINICAL PRACTICE GUIDELINES FOR HYPOTHYROIDISM IN ADULTS: COSPONSORED BY THE AMERICAN ASSOCIATION OF CLINICAL ENDOCRINOLOGISTS AND THE AMERICAN THYROID ASSOCIATION. ENDOCR PRACT. 2012 NOV-DEC; 18(6): 988-1028. [PMID: 23246686](#)
- HAUGEN BR, ET AL. 2015 AMERICAN THYROID ASSOCIATION MANAGEMENT GUIDELINES FOR ADULT PATIENTS WITH THYROID NODULES AND DIFFERENTIATED THYROID CANCER: THE AMERICAN THYROID ASSOCIATION GUIDELINES TASK FORCE ON THYROID NODULES AND DIFFERENTIATED THYROID CANCER. THYROID. 2016; 26(1): 1. [PMID: 26462967](#)
- LAZARUS JH. MANAGEMENT OF HYPERTHYROIDISM IN PREGNANCY. ENDOCRINE. 2014 MAR; 45(2): 190.4. [PMID: 24174179](#)
- LONGO DL, FAUCI AS, KASPER DL, HAUSER SL, JAMESON J, LOSCALZO J. *HARRISON'S MANUAL OF MEDICINE, 18E*; 2014 AVAILABLE AT: [HTTP://ACCESSMEDICINE.MHMEDICAL.COM/CONTENT.ASPX?BOOKID=1140&SECTIONID=63503887](http://accessmedicine.mhmedical.com/content.aspx?bookid=1140&sectionid=63503887) ACCESSED: JANUARY 15, 2018
- PERSANI L. CLINICAL REVIEW: CENTRAL HYPOTHYROIDISM: PATHOGENIC, DIAGNOSTIC, AND THERAPEUTIC CHALLENGES. J CLIN ENDOCRINOL METAB. 2012 SEP; 97(9): 3068-7. [PMID: 22851492](#)
- SHARMA A, BAUMANN NA, SHAH P. BIOTIN-INDUCED BIOCHEMICAL GRAVES DISEASE: A TEACHABLE MOMENT. JAMA INTERN MED. 2017; 177(4): 571. [PMID: 28192572](#)
- SWEENEY LB, STEWART C, GAITONDE DY. THYROIDITIS: AN INTEGRATED APPROACH. AM FAM PHYSICIAN. 2014 SEP 15;90(6):389-96. [PMID: 25251231](#)
- TABATABAIE V, SURKS MI. THE AGING THYROID. CURR OPIN ENDOCRINOL DIABETES OBES. 2013 OCT;20(5):455-9. [PMID: 23974775](#)
- VAIDYA B, PEARCE SH. DIAGNOSIS AND MANAGEMENT OF THYROTOXICOSIS. BMJ. 2014 AUG 21;349:G5128. [PMID: 25146390](#)