

HOW I APPROACH COVID 19 OSTEOPATHICALLY

Phillip A. Nokes, D.O.

Mid Winter CME Hard Rock Hotel

Tulsa, Oklahoma Jan 2023

I have no financial interest in anything expressed or implied in this lecture. I have no conflict of interest that I know of with any of this presentation.

Phillip A. Nokes, D.O.
Diplomate of the ACOFP

PRESENTATION TITLE

INTRO- DUCTION

Goals are to reintroduce us to the Osteopathic mindset in treating Covid-19

Brief review of pathology of Covid-19

Lymphatic involvement in disease

Treatment options with proven effectiveness

Questions?

PTICE[®]

A MEMBER OF THE MDEDGE NETWORK MDedge

GUEST EDITORIAL

Going the distance
with our patients

PAGE 330

APPLIED EVIDENCE

COVID-19 vaccine insights:
The news beyond the headlines

PAGE 332

PURLS[®]

Skip the biopsy for celiac
diagnosis in adults?

PAGE 359

PRACTICE ALERT

Vaccine update for the 2022-23
influenza season

PAGE 362

Dx ACROSS THE SKIN COLOR SPECTRUM

Tinea capitis

PAGE 370

CLINICAL INQUIRIES

Does an early COPD diagnosis
improve long-term outcomes?

PAGE 372

PHOTO ROUNDS

Osteopathic Family Physician

EDITOR'S MESSAGE

Our Commitment to Serve

FROM THE PRESIDENT'S DESK

Fellowship and Family: Engendering
Lifelong Connections

REVIEW ARTICLES

Home Blood Glucose Monitoring

COVID-19 in Patients with Asthma:
Review and Implications for Care of
Adult Patients with an Osteopathic
Component

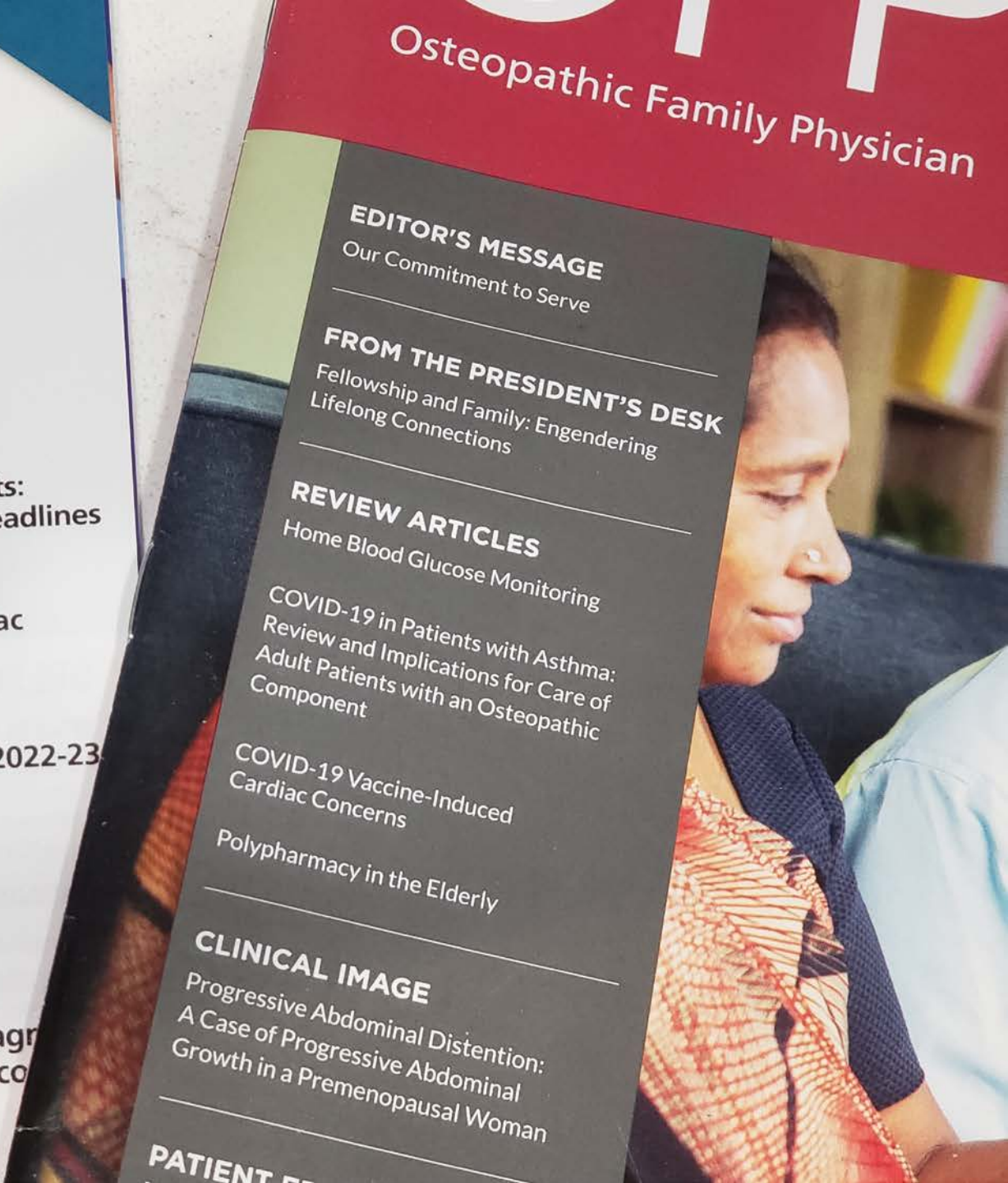
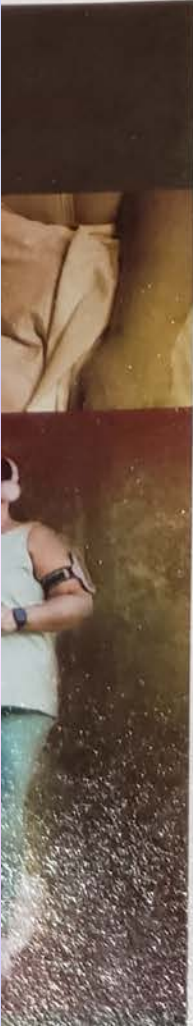COVID-19 Vaccine-Induced
Cardiac Concerns

Polypharmacy in the Elderly

CLINICAL IMAGE

Progressive Abdominal Distention:
A Case of Progressive Abdominal
Growth in a Premenopausal Woman

PATIENT FE



EDITOR'S MESSAGE

Caring as a Community

FROM THE PRESIDENT'S DESK

Making a Statement to Make an Impact

REVIEW ARTICLES

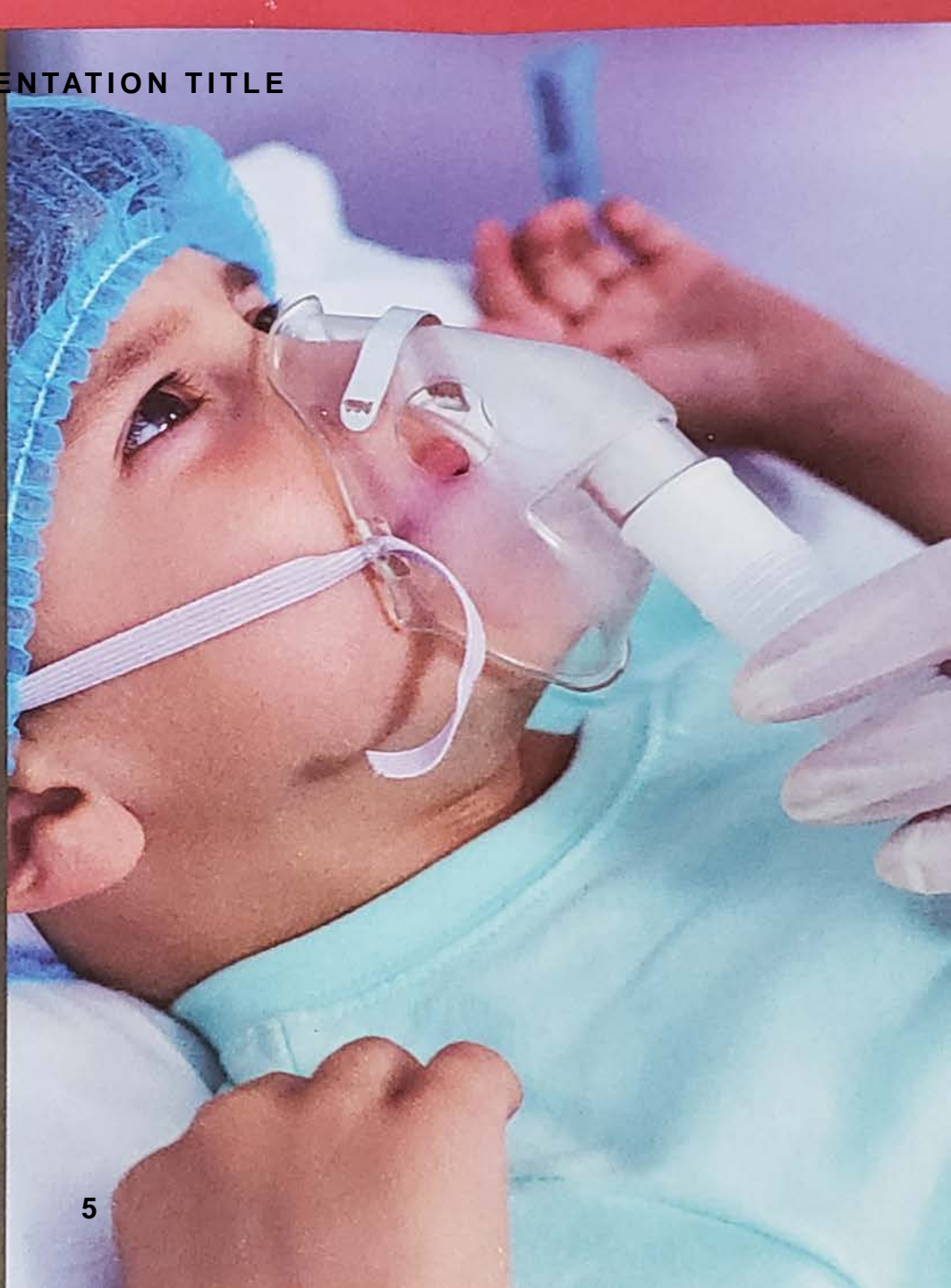An Osteopathic Approach to Anemia

Identifying Multisystem Inflammatory Syndrome in Children After COVID-19 Infection

BRIEF REPORTS

Leveraging Primary Care, Public Health and Social Context During the COVID-19 Response Within in a University Setting: Considerations for the Osteopathic Family Physician

Dermoscopy Curriculum in Family Medicine Residency Bridges Gap Between Dermatological Care of Skin Melanoma in Rural Underserved



The incidence of Myocarditis and Pericarditis in Post COVID-19 unvaccinated Patients – A Large Population – Based Study (192,992 patients) Ortel Tuvali et al. J. Clin Med 2022

“We did not observe an increase of Pericarditis or Myocarditis in unvaccinated adult patients recovering from COVID-19 infections”

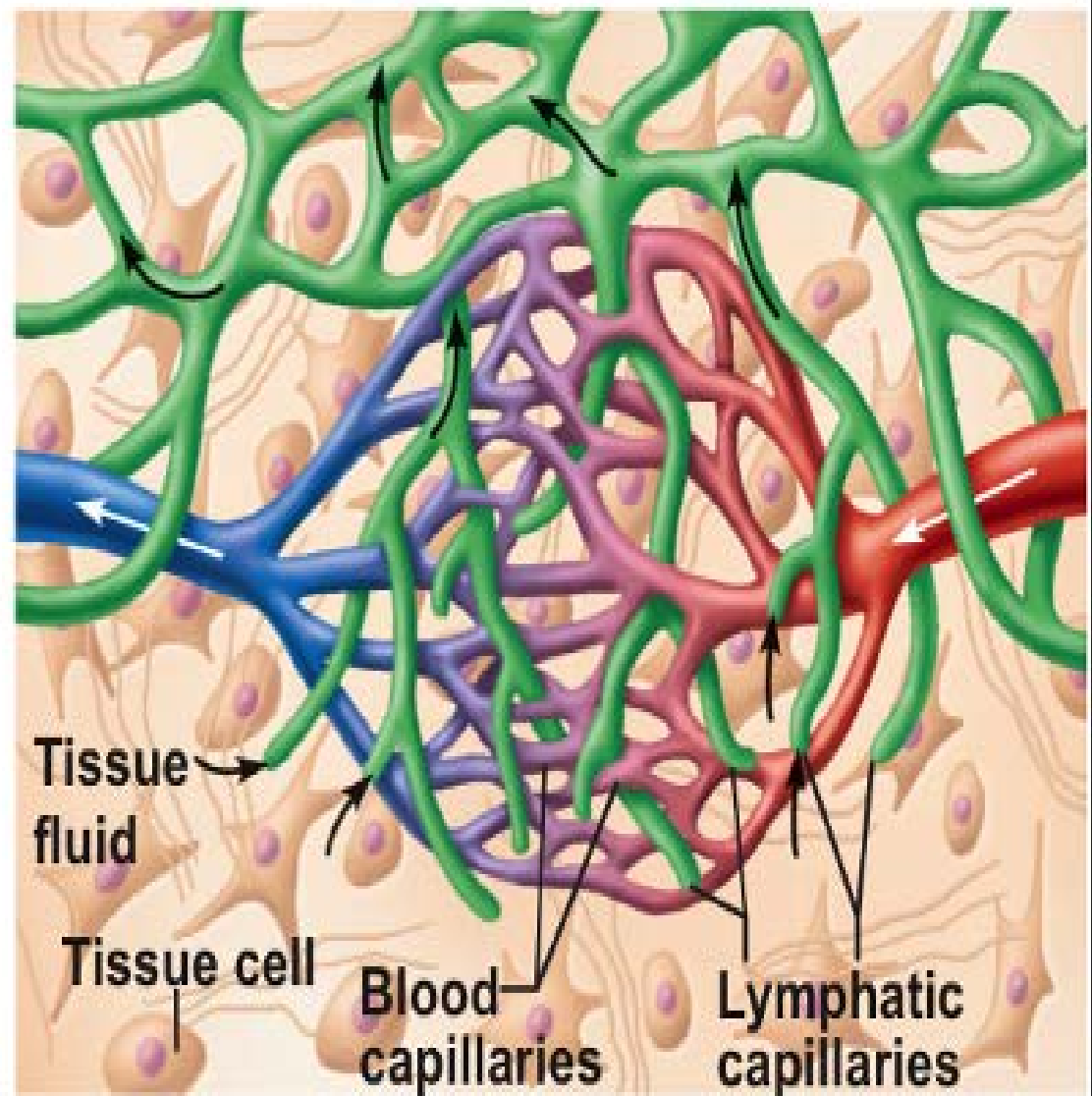
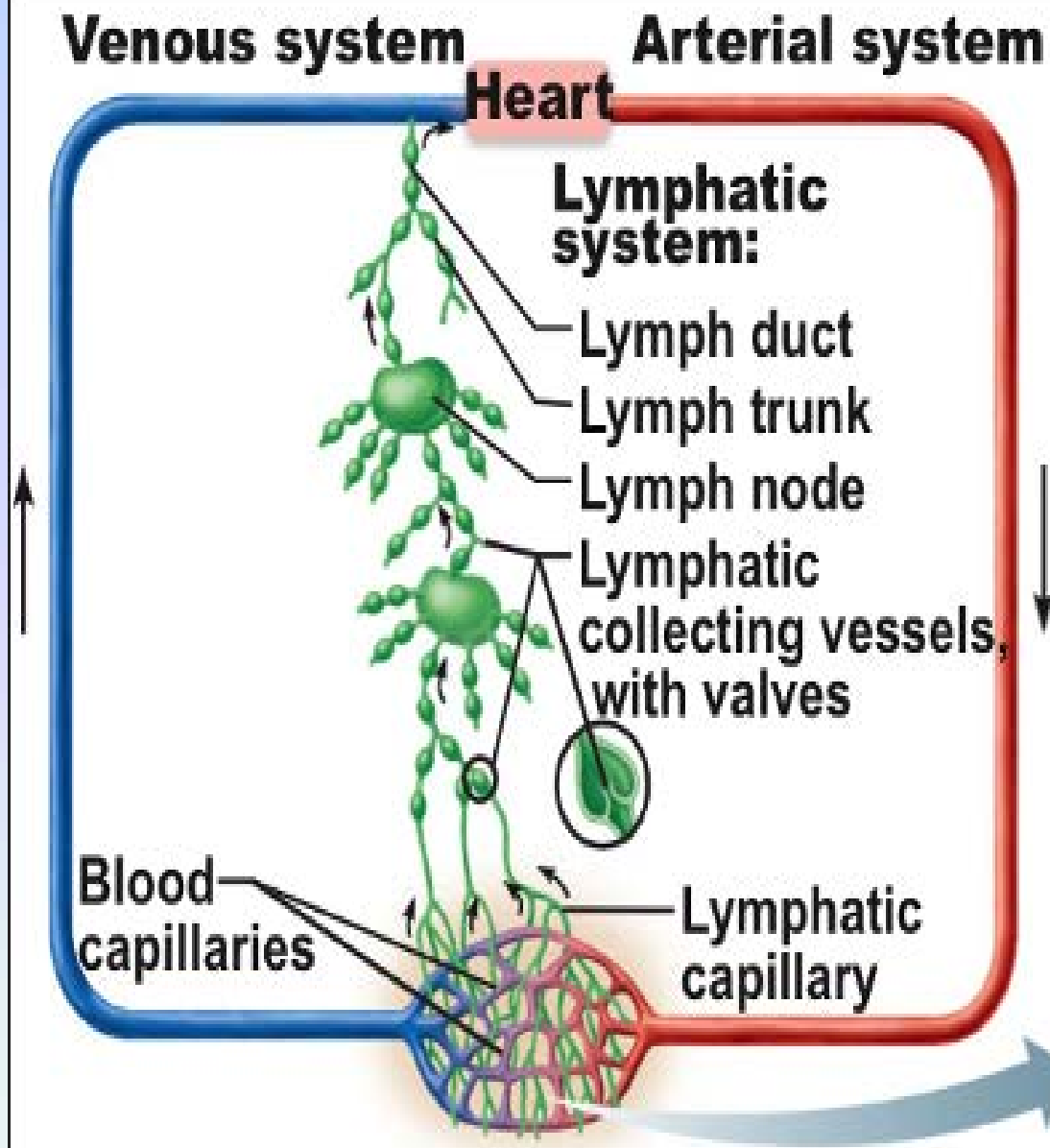
PRESENTATION TITLE

The FDA's website states that if a viable treatment exists for an illness during a health emergency, neither medications nor vaccines may be approved using an emergency use authorization.

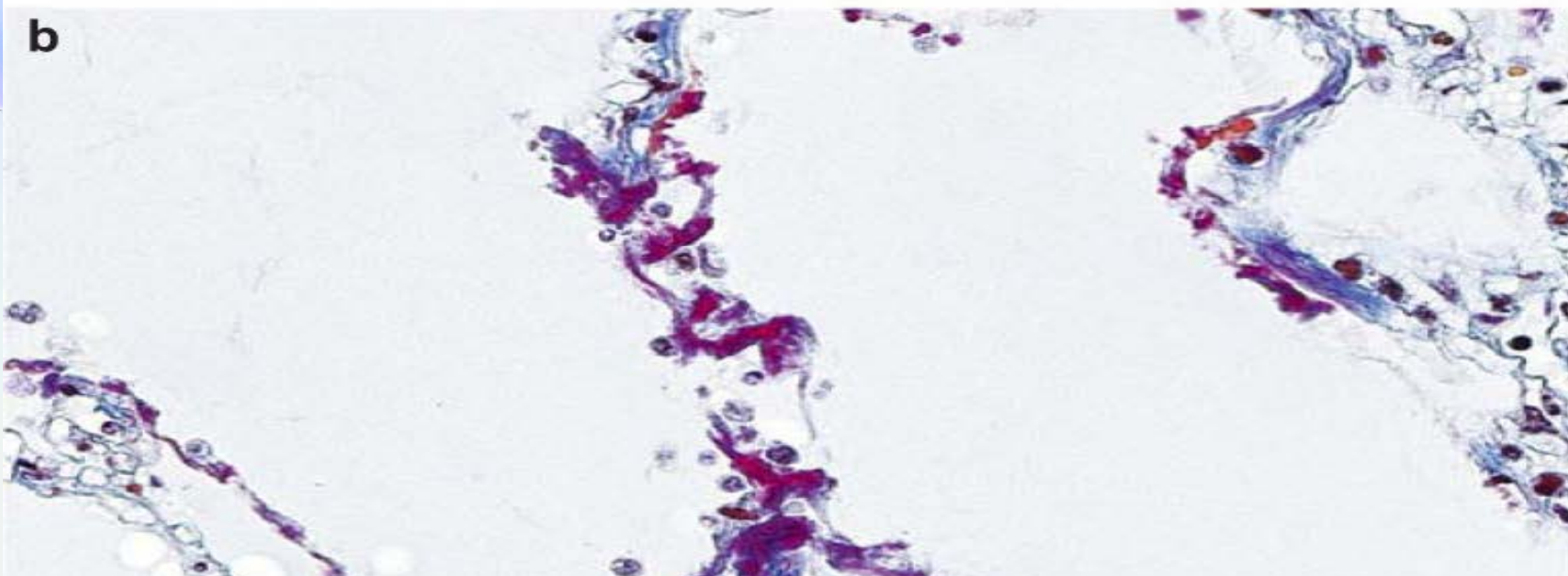
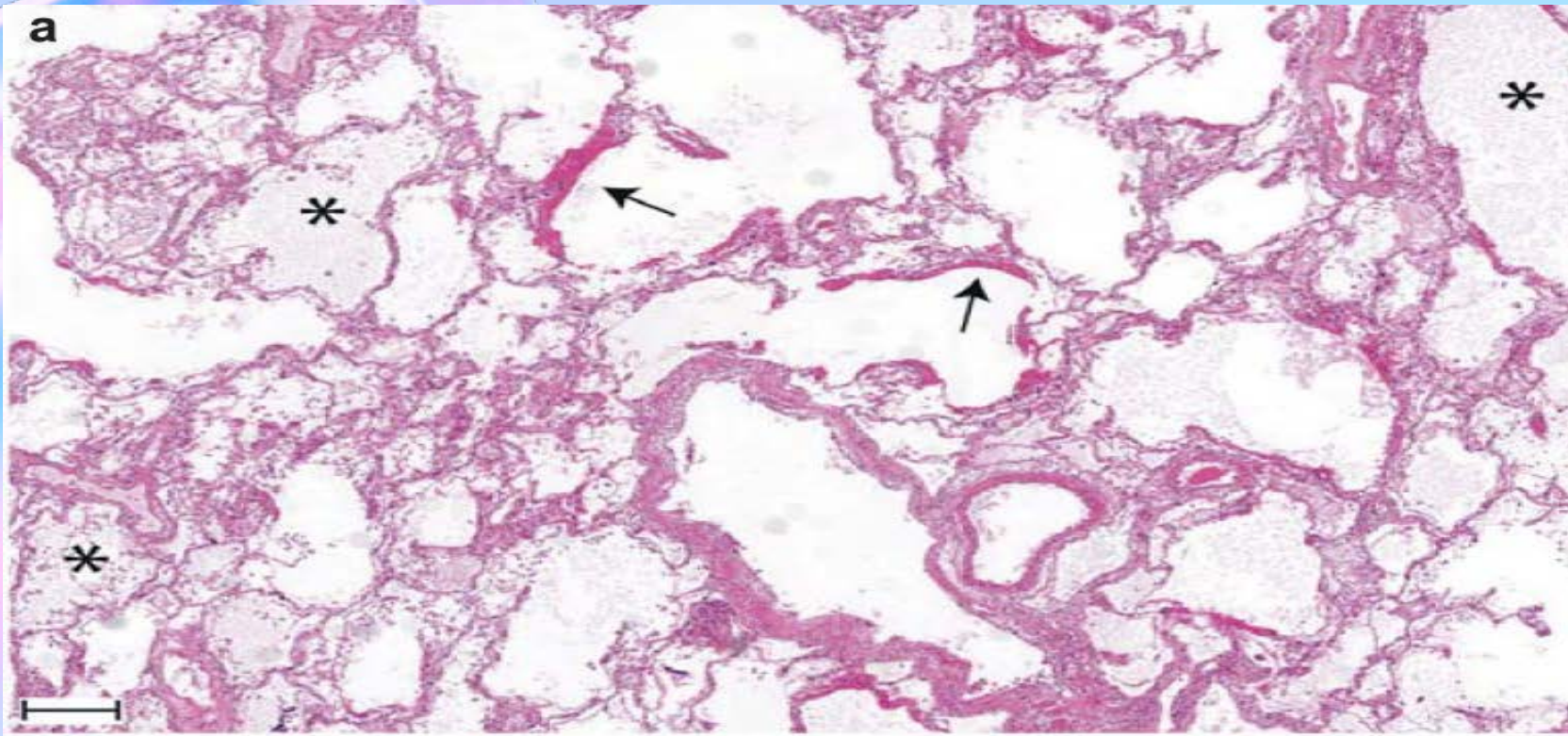
While there isn't concrete proof for their position, some doctors and nurses interviewed by The Epoch Times theorized that the FDA's pushback against ivermectin was motivated by the need to secure an emergency use authorization for the COVID-19 vaccines.

"They had an agenda. And the agenda was to push this new form of vaccine, this mRNA vaccine, because it was going to make the industry billions of dollars. And in order for them to promote this because they didn't have the time to do randomized control trials for efficacy and safety, they had to use Emergency Use Authorization [EAU]," Saleeby said.

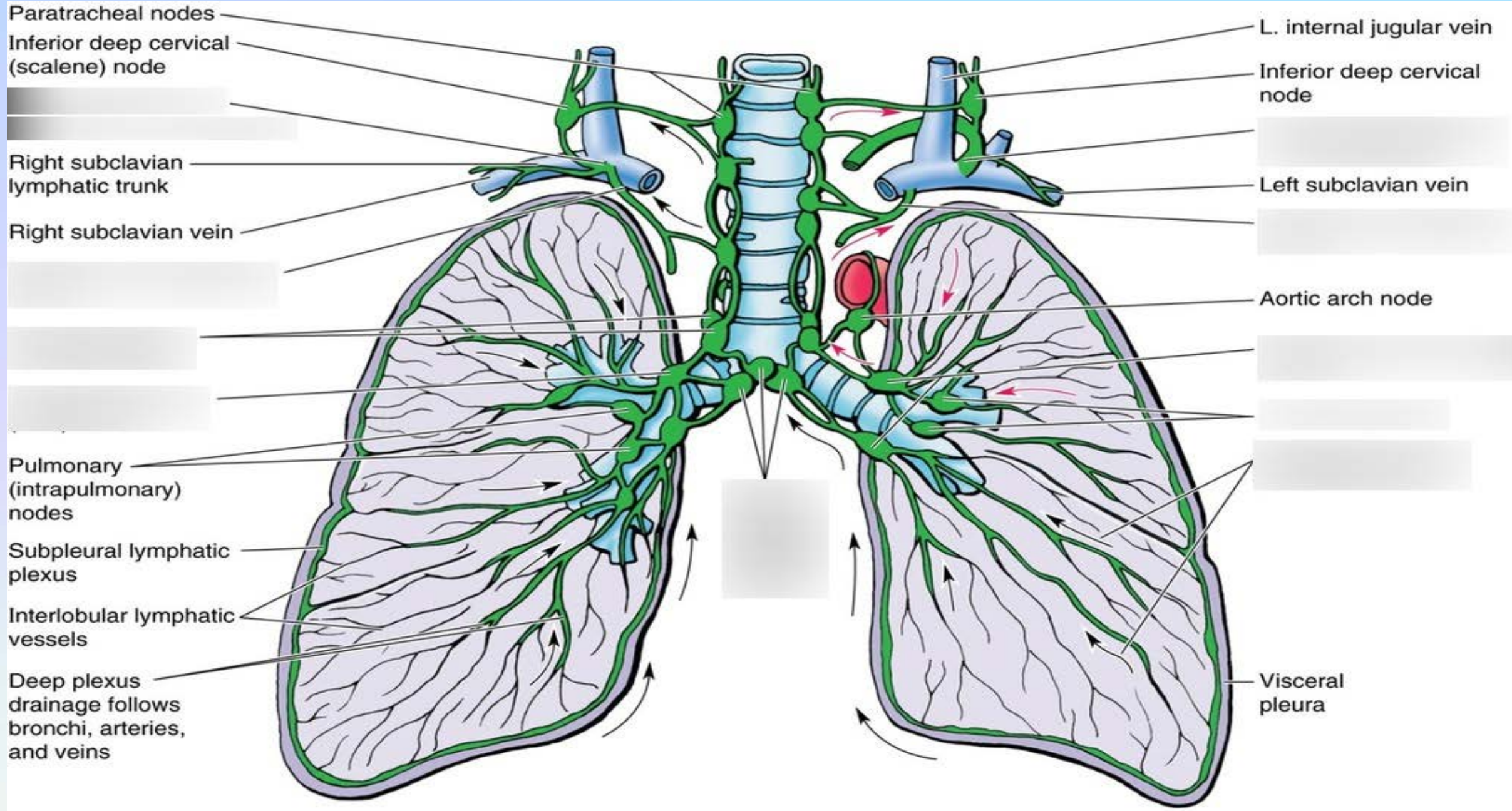
It completely destroys the vaccine position,” Dark concurred. “One thing that’s written very clearly is that you cannot have a known acceptable form of treatment out there available to the public and still be operating under emergency use.” “If there was a possible treatment for COVID-19, the vaccine would not be able to obtain emergency authorization use,” Wright said. “If there’s any possible treatment, then the vaccines would have to go through rigorous testing.”



(a) Structural relationship between a capillary bed of the blood vascular system and lymphatic capillaries.

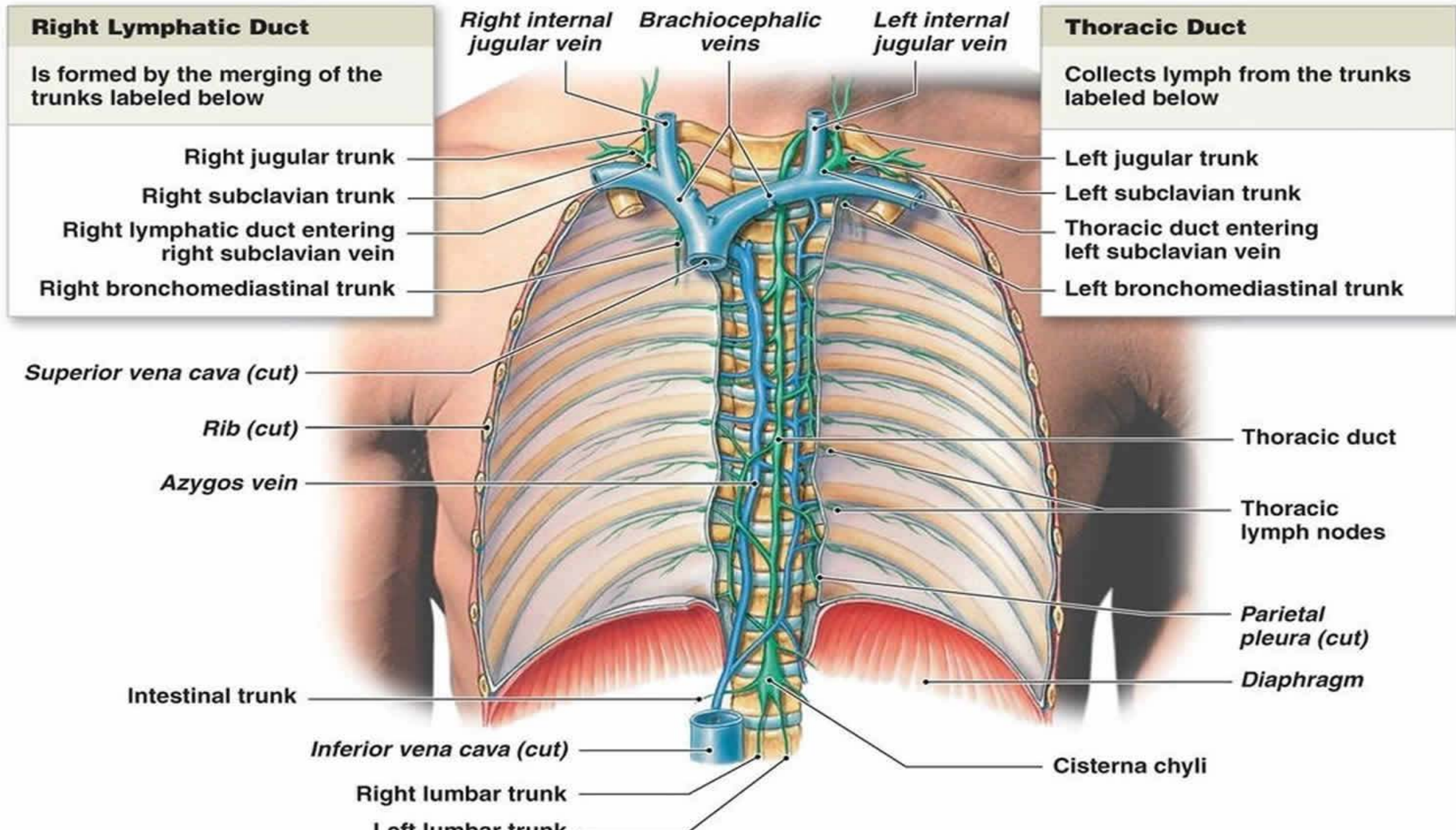


[Dtsch Arztebl Int. 2020 Jul; 117\(29-30\): 500–506.](#)
Published online 2020 Jul 20.
doi: [10.3238/arztebl.2020.0500](https://doi.org/10.3238/arztebl.2020.0500)

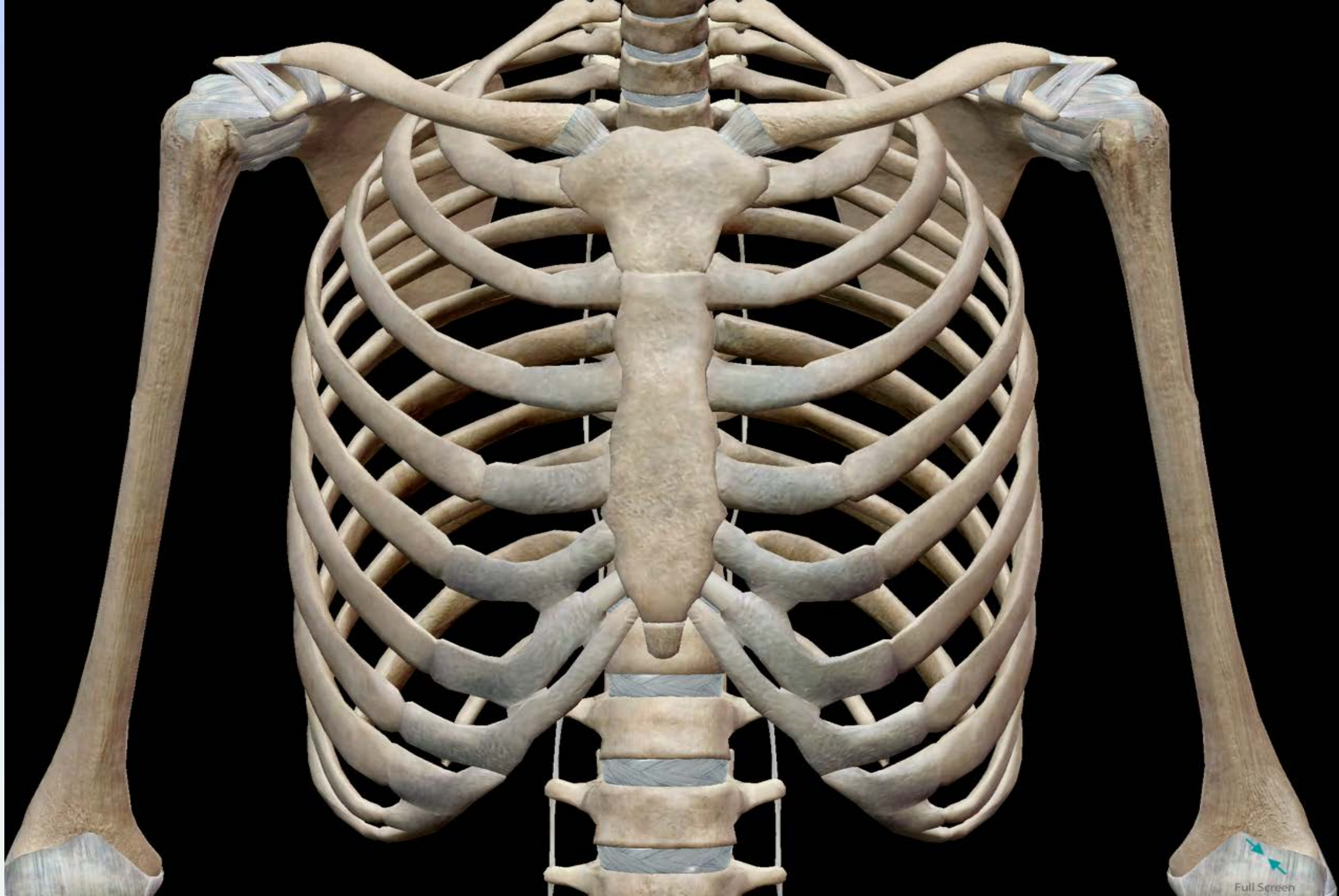


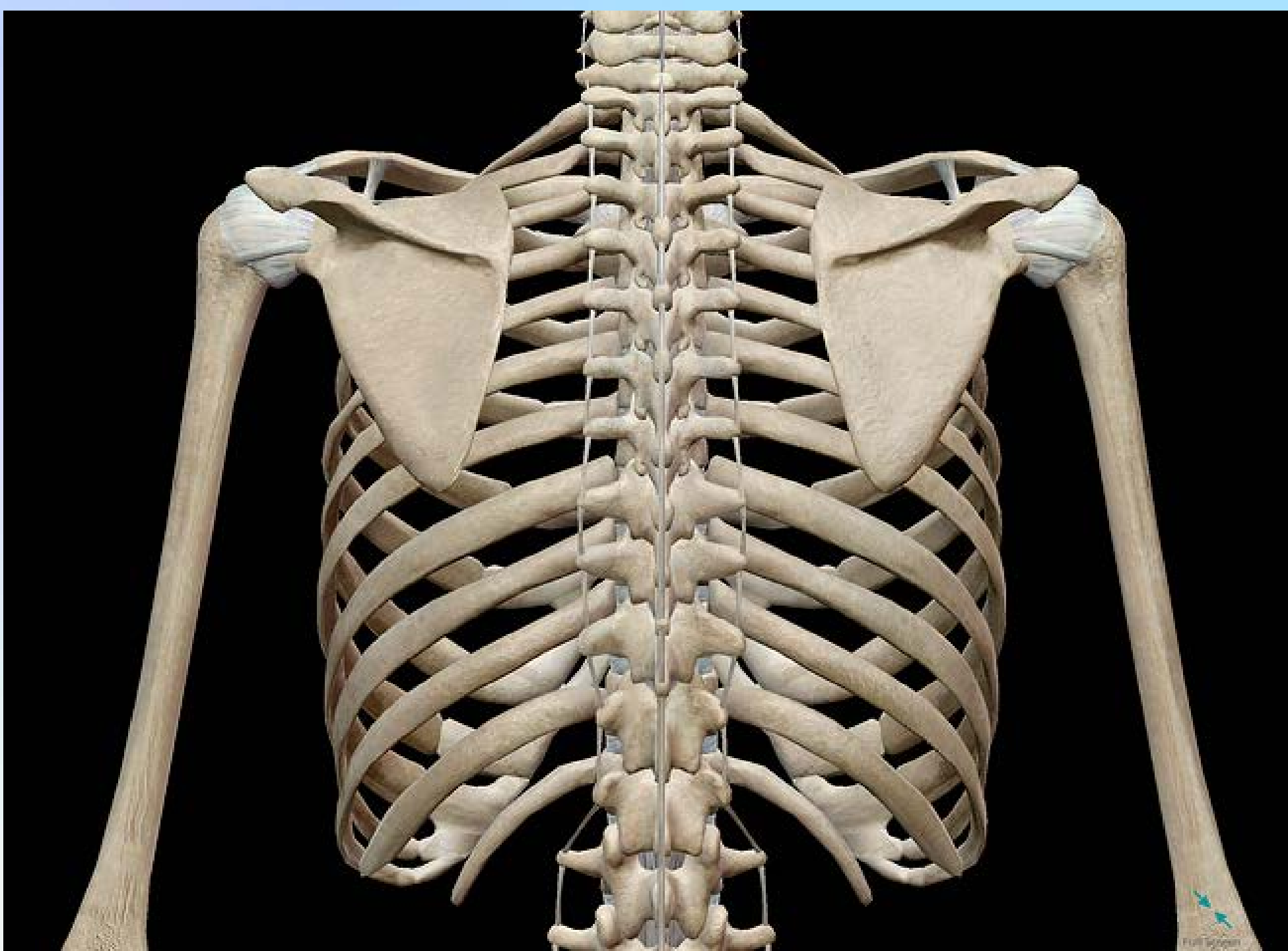
➤ = Drainage from left superior lobe ➤ = Drainage from right lung and left inferior lobe

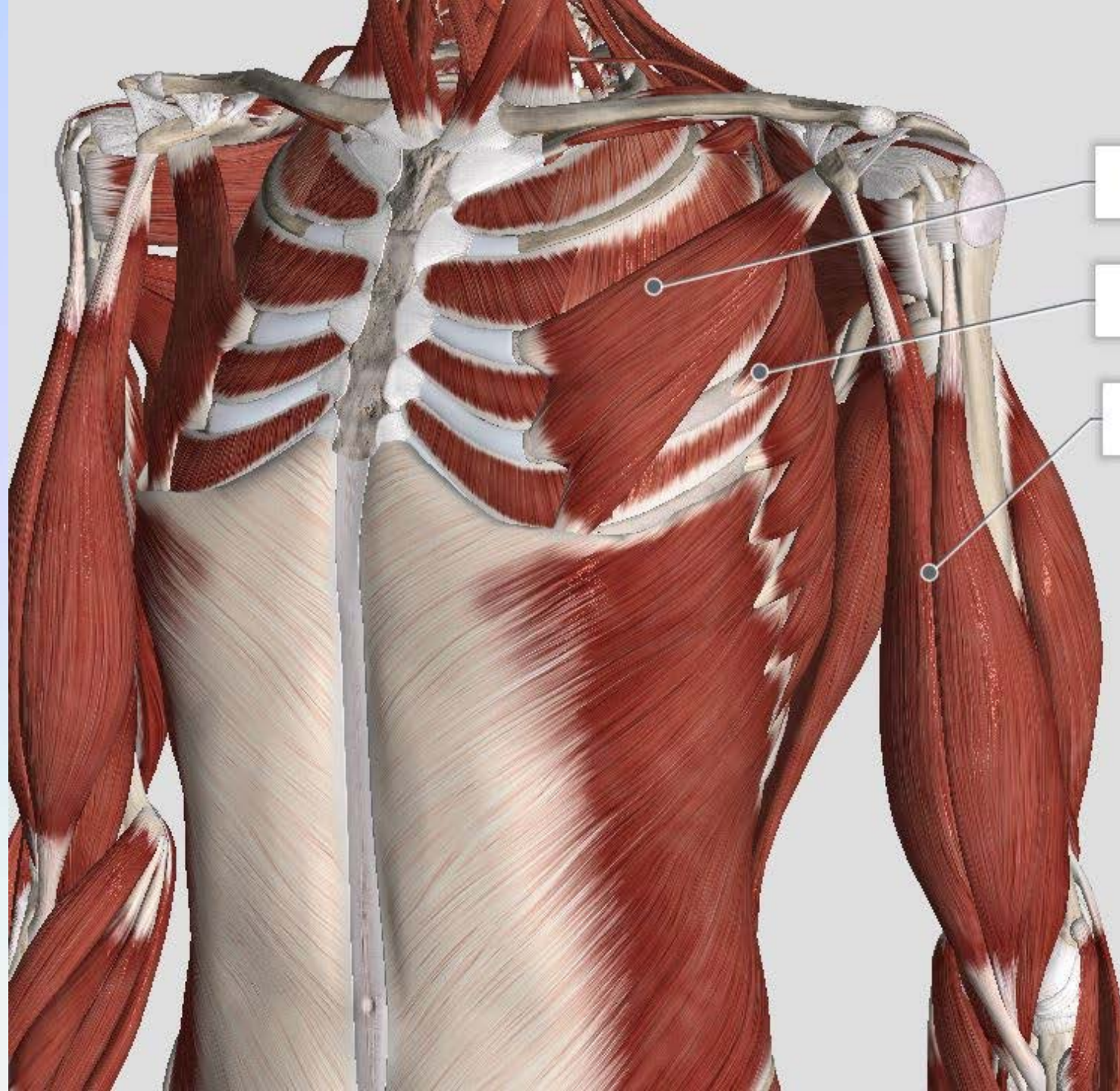
The relationship between the right lymphatic and thoracic ducts and the venous system







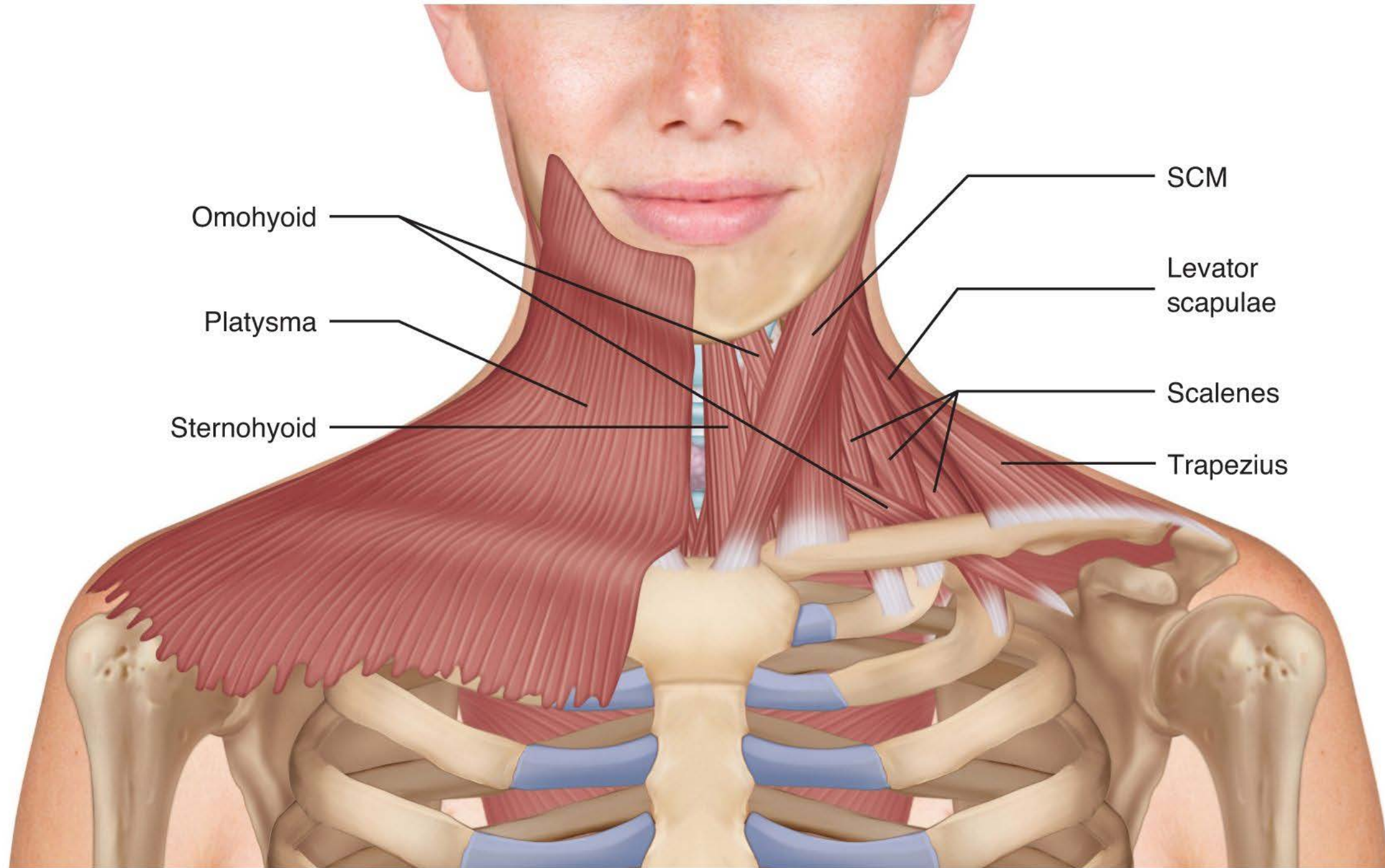




Pectoralis Minor

Serratus Anterior

Arm



Omohyoid

Platysma

Sternohyoid

SCM

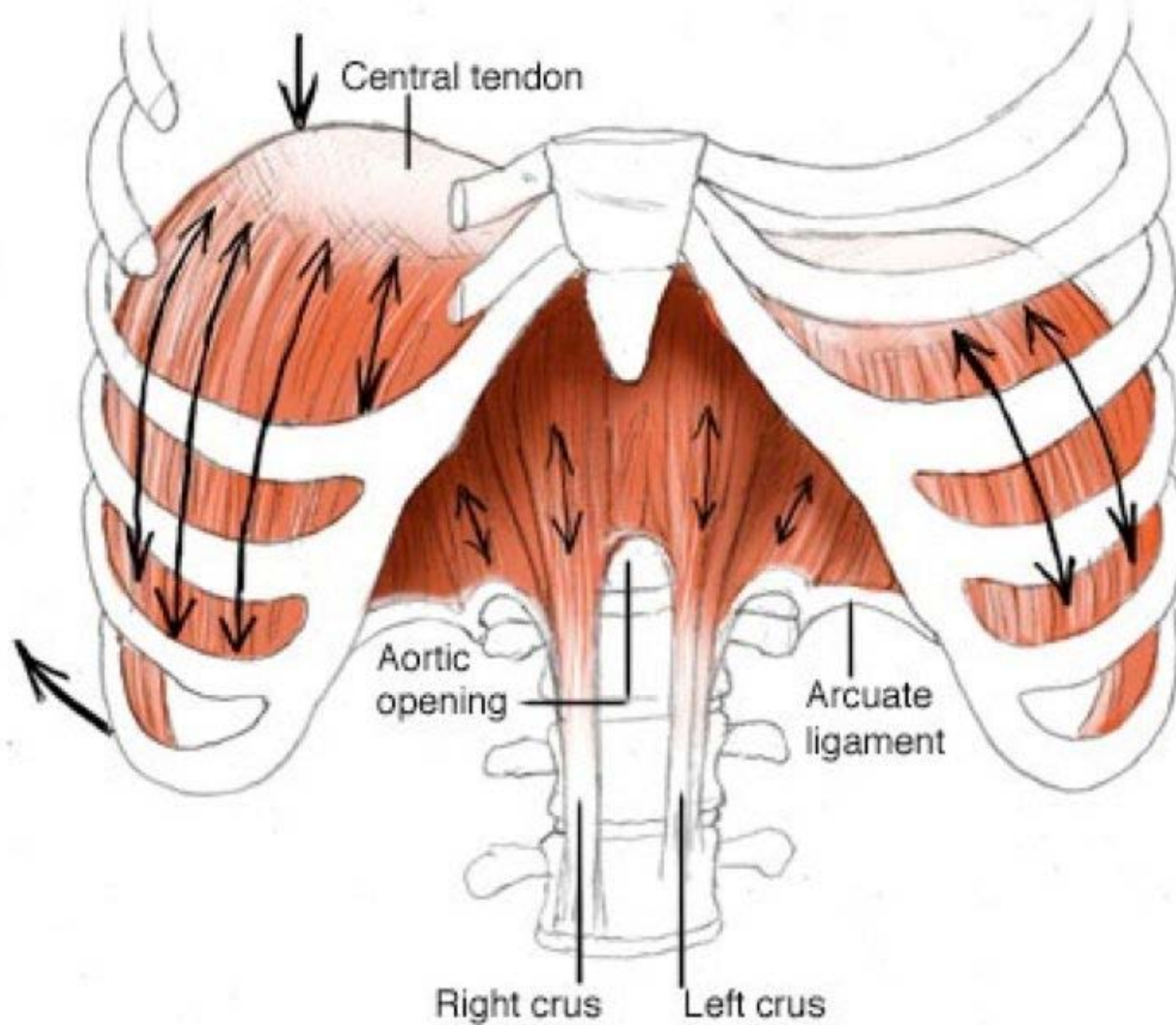
Levator
scapulae

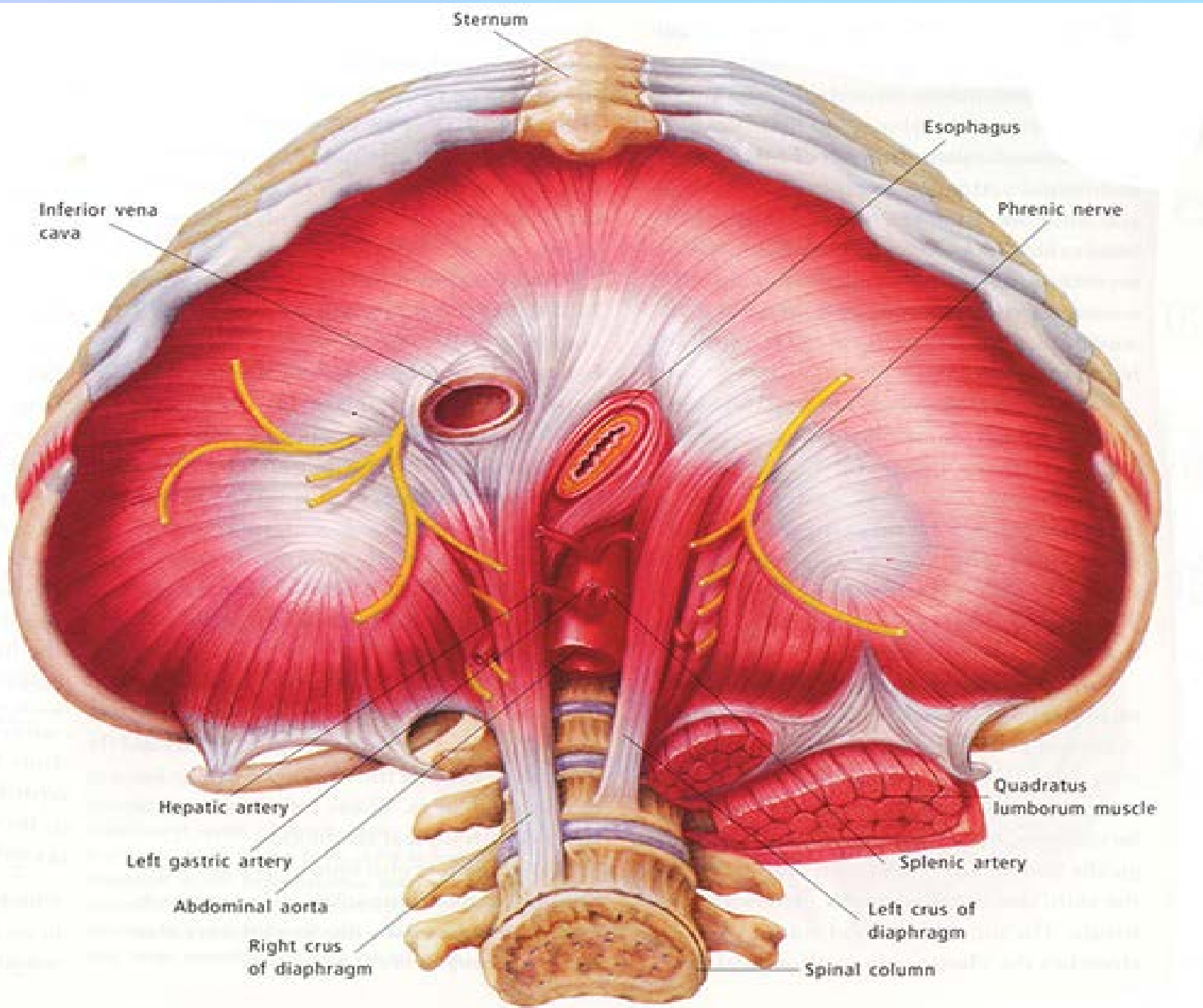
Scalenes

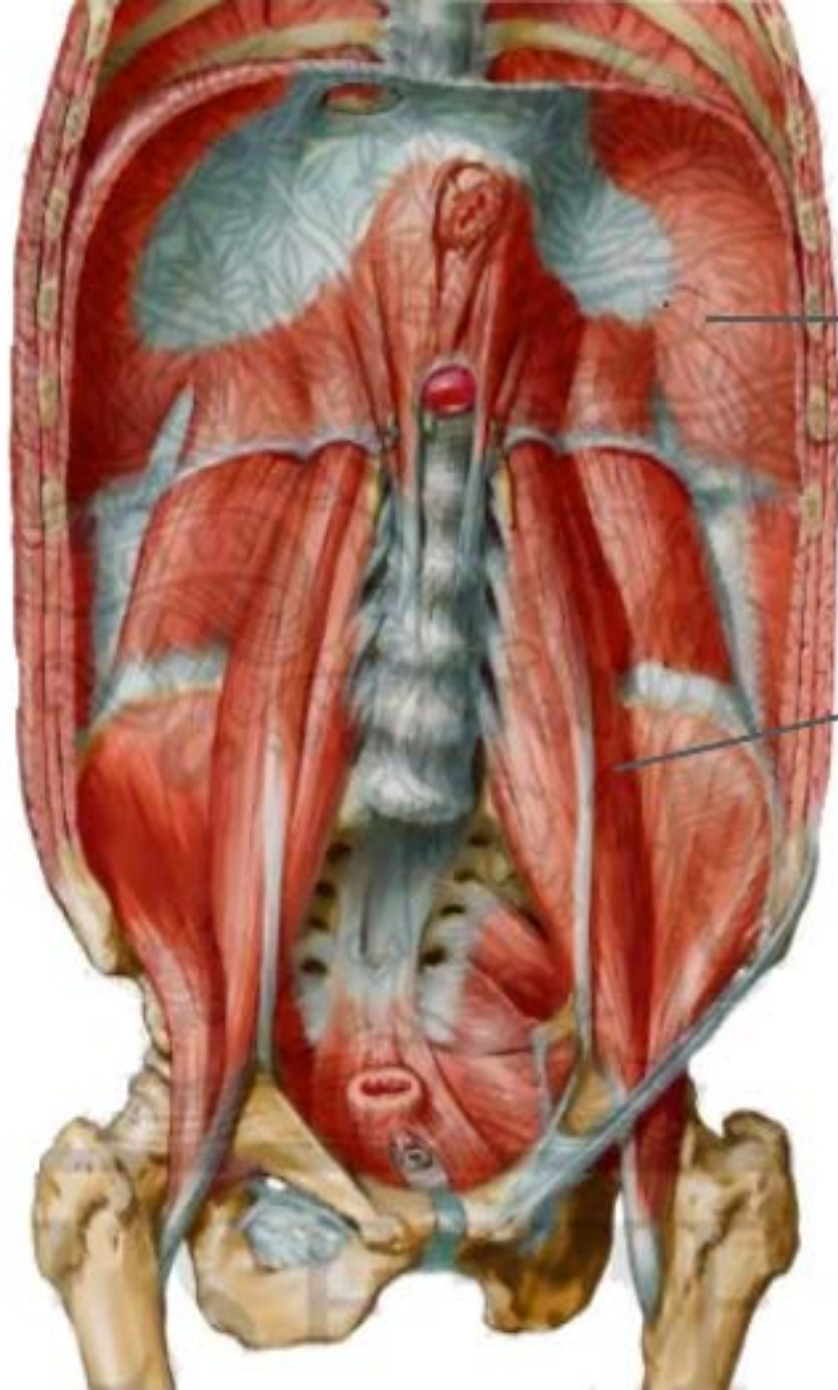Trapezius

A

Direction of Muscle Action of the Diaphragm







Diaphragm

Psoas



NUTRITIONAL CONSIDERATIONS

1. Vitamin D 5000 IU daily and double if one has covid
2. Zinc at 75 mg daily
3. Vitamin C (powdered form) 1000 mg a day and double if one has covid
4. Selenium 50 ug a day
5. Fluids to stay hydrated and need to eat small meals at least 3 times a day

LYMPHATIC DRAINAGE OF THE CHEST, NECK AND ABDOMEN

1. Techniques for the neck
2. Techniques for the chest
3. Techniques for the abdomen
4. Techniques for the lower extremities



THANK YOU

Phillip A. Nokes, D.O.

panokes78@gmail.com

405-269-0479

1. INCIDENCE OF MYOCARDITIS AND PERICARDITIS IN POST
NONVACCINATED COVID19 PATIENTS – ORTEL TUVALI ET ALL. J CLIN
MED 2022

2. COVID-19 VACCINE-INDUCED CARDIAC CONCERNS B. CUSACK,
D.O., PUNEET TUNG, D.O. KATIE MCHALE, D.O., BRANDT GROH, MD,
OFP NOVEMBER/DECEMBER VOLUME 14/NUMBER 6, PAGES 22-24

3. COVID-19 VACCINE INSIGHTS: NEWS BEYOND THE HEADLINES J
OF FP PAGE 332-339 VOL 71/NO 8, OCTOBER 2022

4. IDENTIFYING MULTISYSTEM INFLAMMATORY IN CHILDREN AFTER
COVID-19 INFECTION ANTHONY MCKEIVER, OMS-IV; GAUTAM J.
DESAI, DO, FACOFP DIST.; W. JOSHUA COX, DO, FACOFP, PAGES 16-21
OFP, SEP/OCT, VOLUME 14/NO 5
